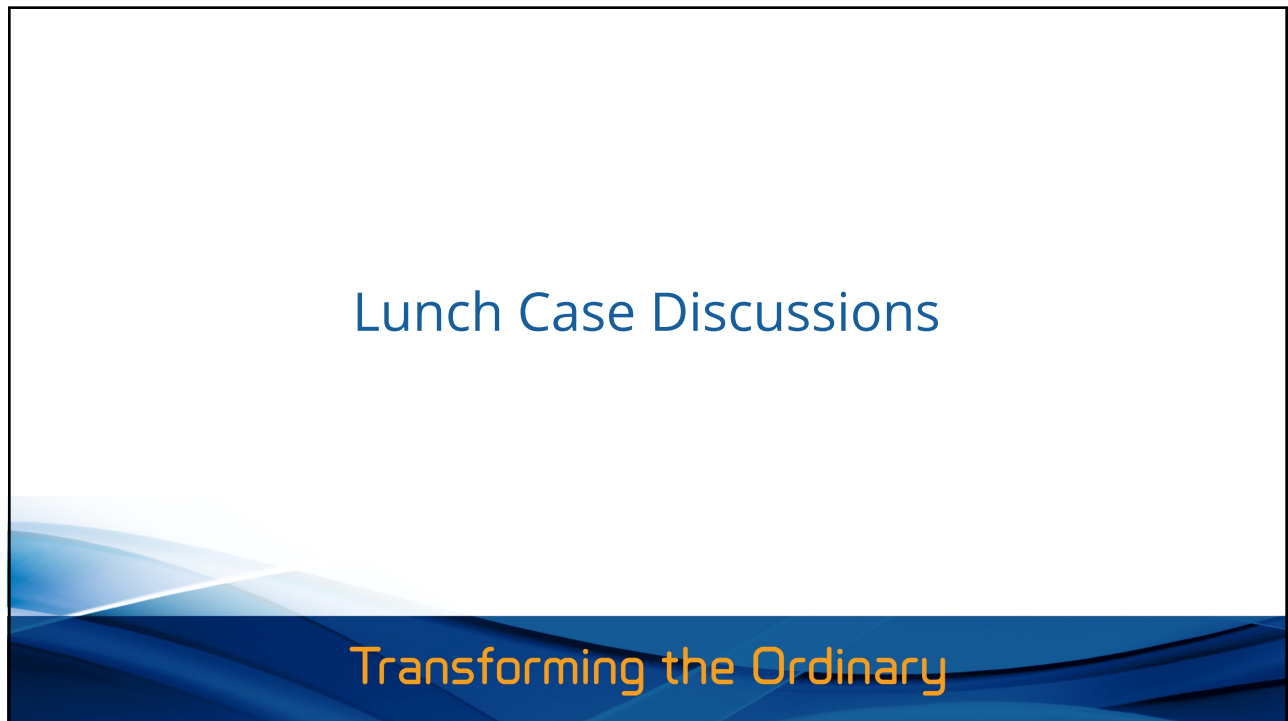

1



2

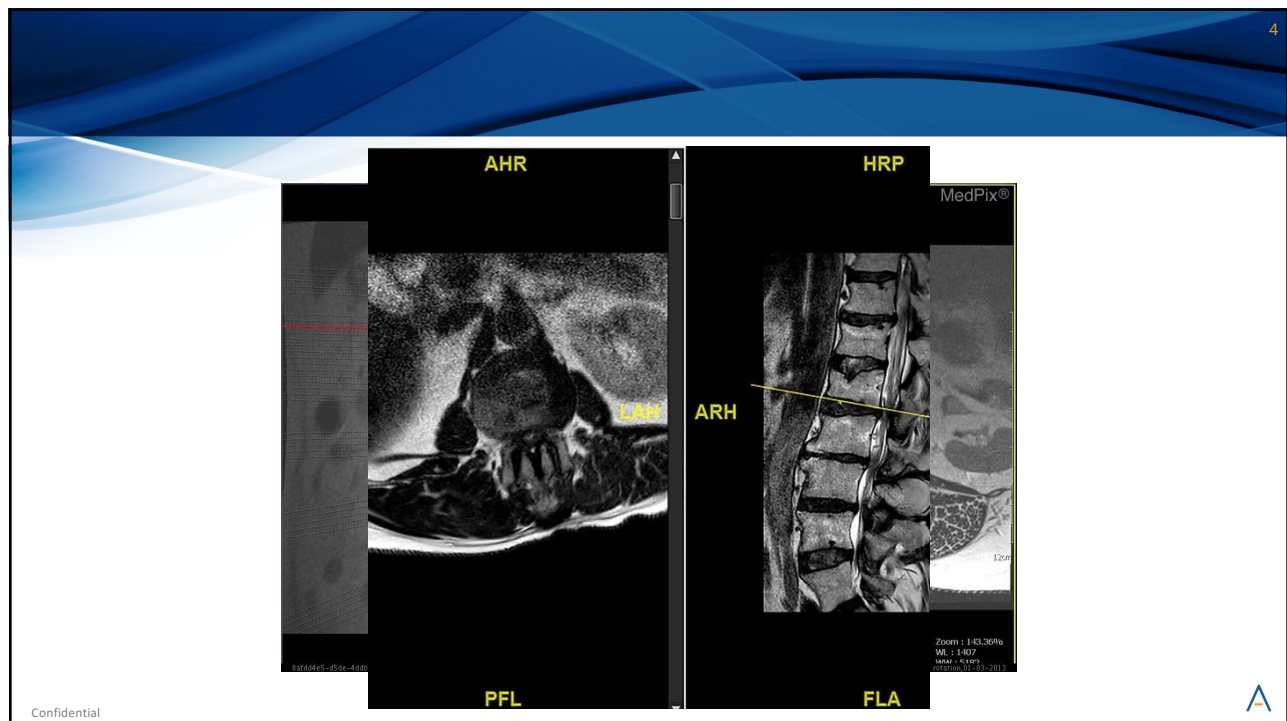Case 1

- 62 year old male with LBP, groin pain with the left side worse than the right for 6 months. Tried pain medications, PT, acupuncture, chiropractic treatment. ESI gave temporary relief for 1 week. No bowel or bladder incontinence.

Confidential



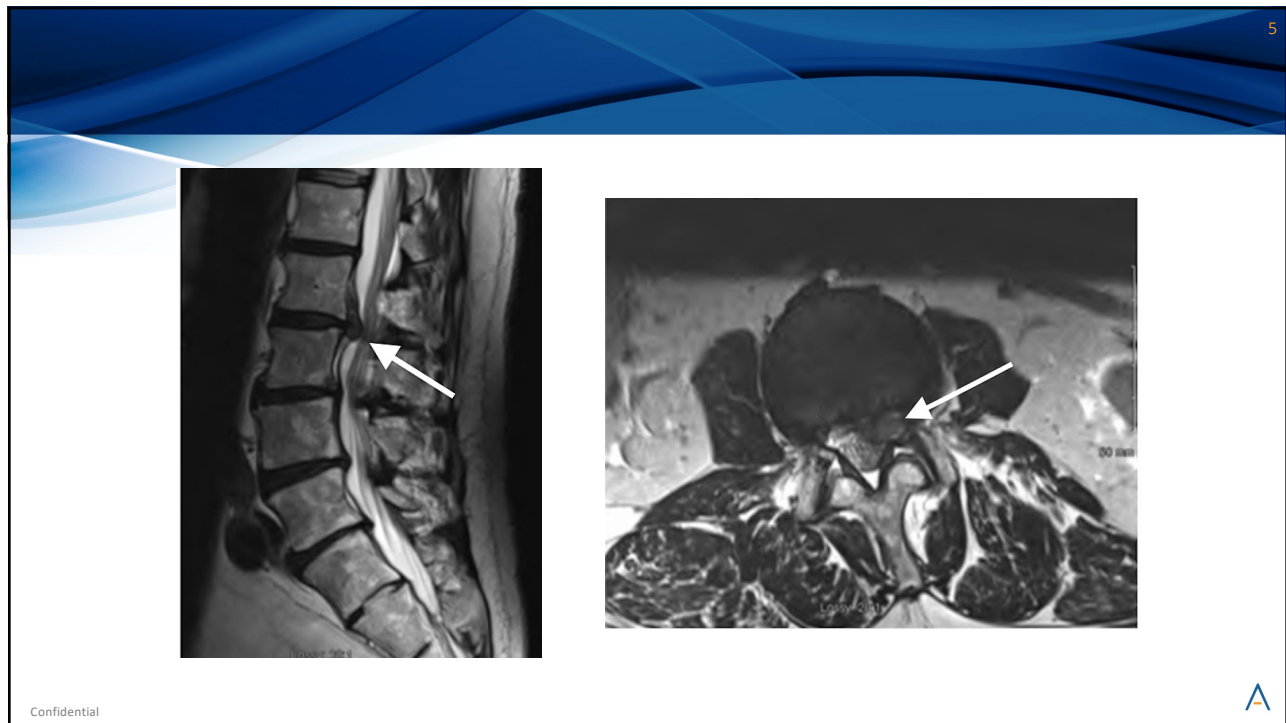3



Confidential



4



5

6

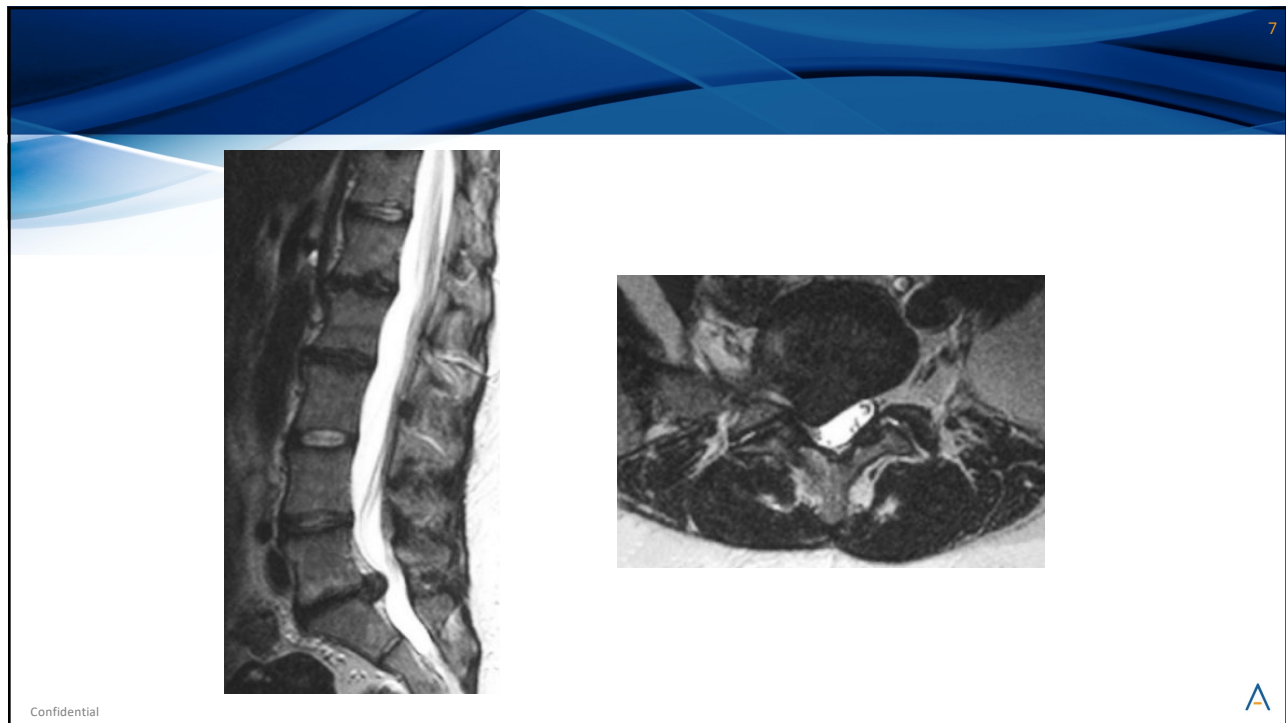Case 2

- 35 year old healthy active male who is a professional MMA fighter developed acute severe back pain with right lower extremity pain radiating to the posterior lower leg and lateral foot with numbness and tingling. He has tried pain meds, PT, ESI without any relief. No bowel or bladder incontinence.

Confidential

A

6



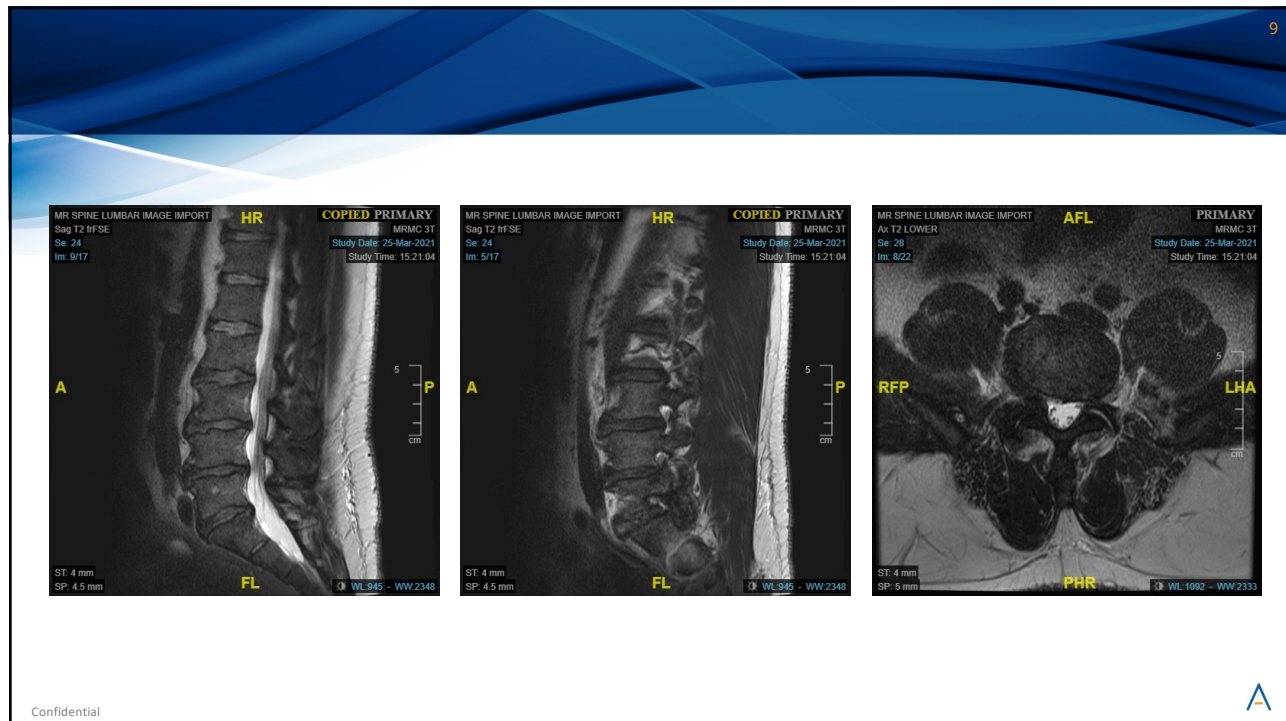
7

Case 3

- 50 year old male with LBP, right lower extremity pain that radiates to the lateral lower leg and dorsal foot with numbness and tingling. No weakness. He had worsening of pain after weightlifting while incarcerated. He tried pain meds, PT, marijuana, ESIs without relief.

Confidential

8



9

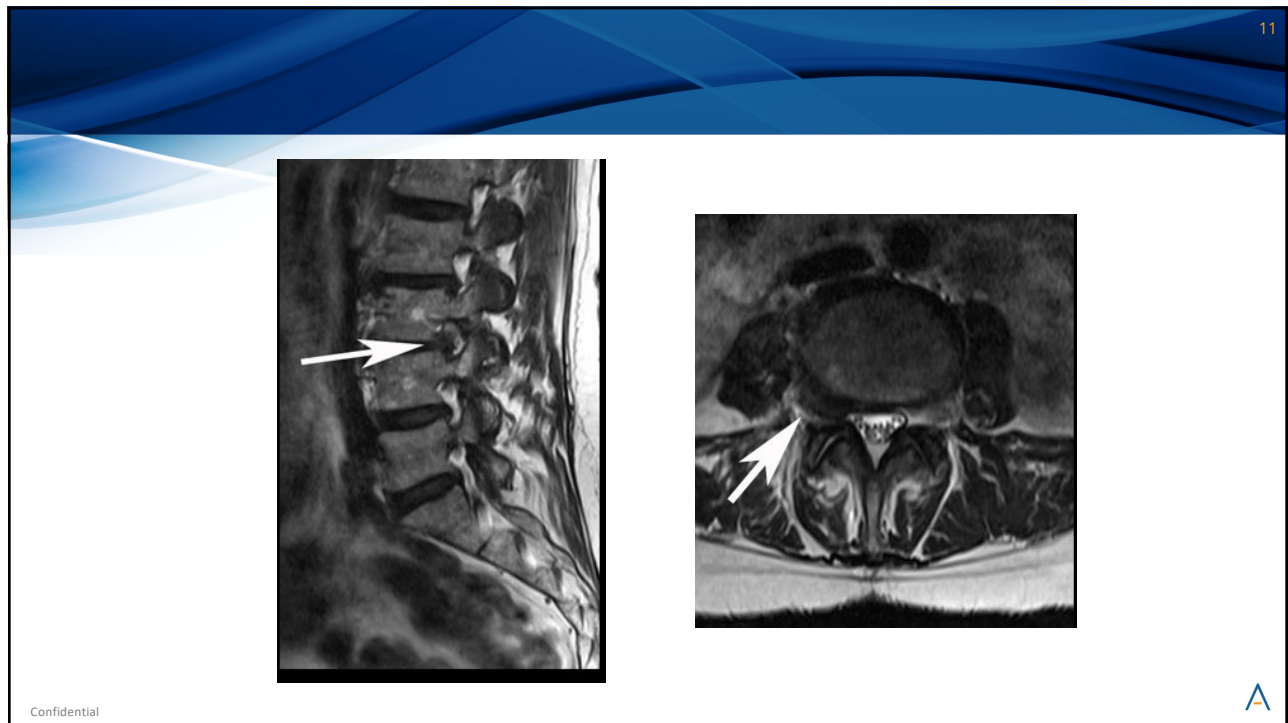
10

Case 4

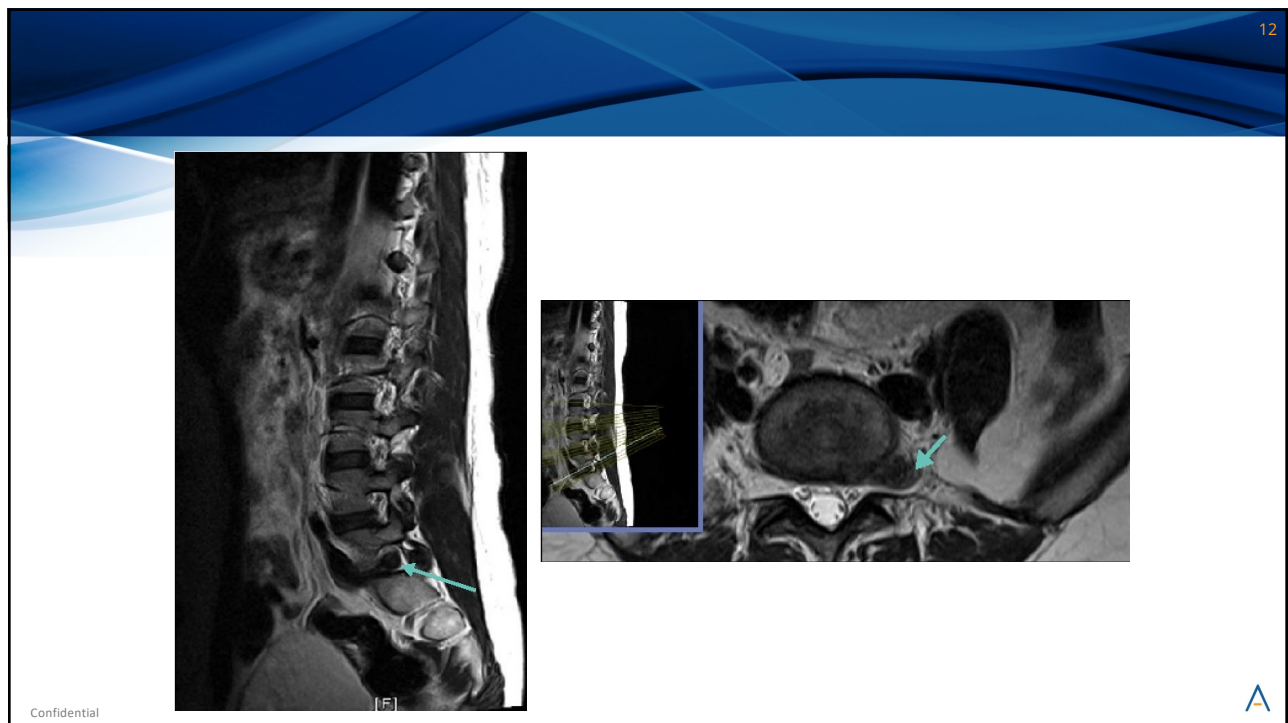
- 45 year old female with right sided anterior thigh burning and numbness. Worsened after working out doing CrossFit boot camp. Failed pain medications, PT, ESIs with continued pain.

Confidential

10



11



12