A surgeon is performing a biportal endoscopic approach for a cervical spine procedure. The surgeon's hands are visible, holding two endoscopic portals. The surgical field is illuminated, and the spine is visible through the portals. The text is overlaid on the image.

# Posterior cervical approaches Biportal Endoscopy

**Dong Hwa Heo. MD. PhD.**

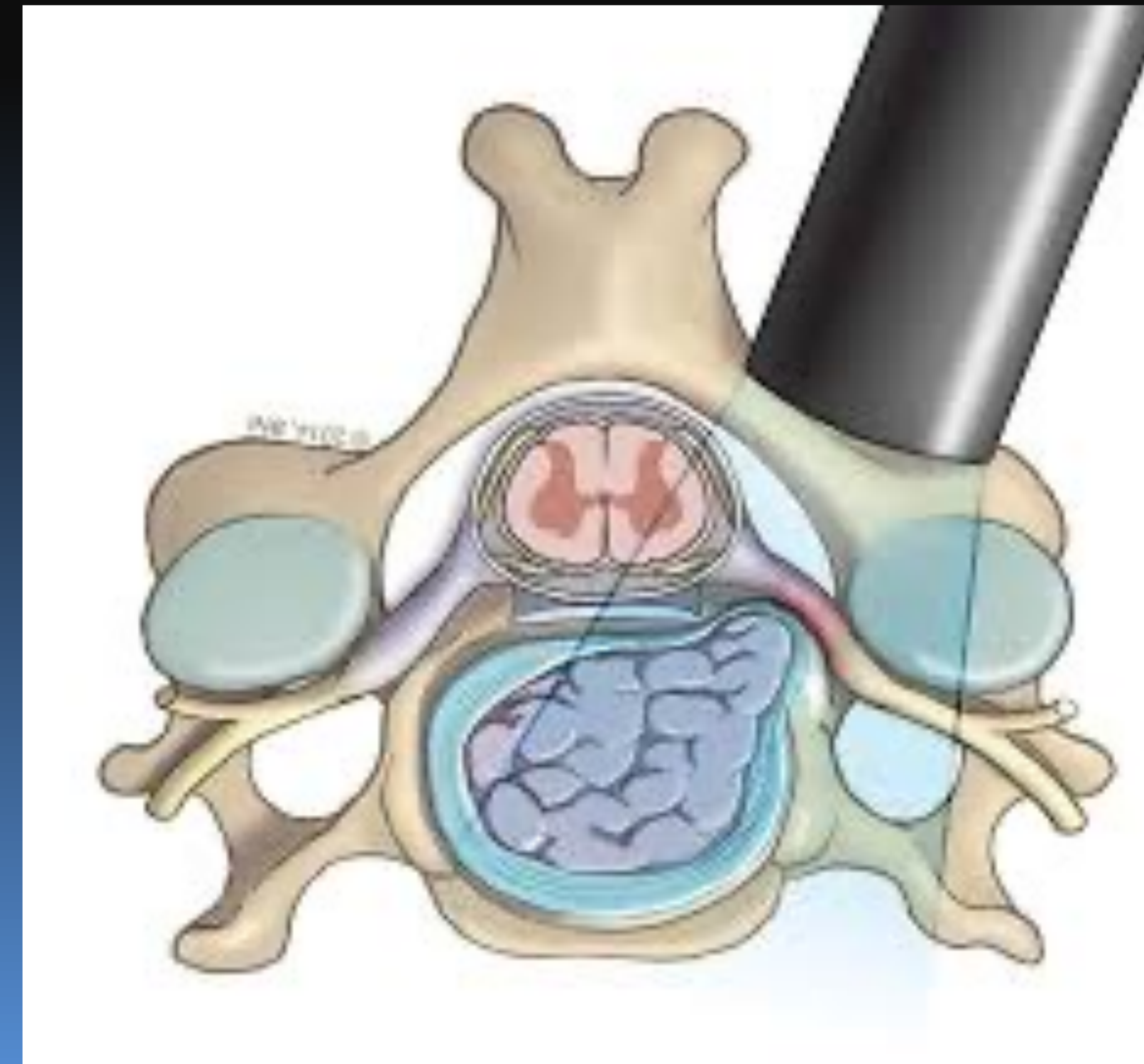
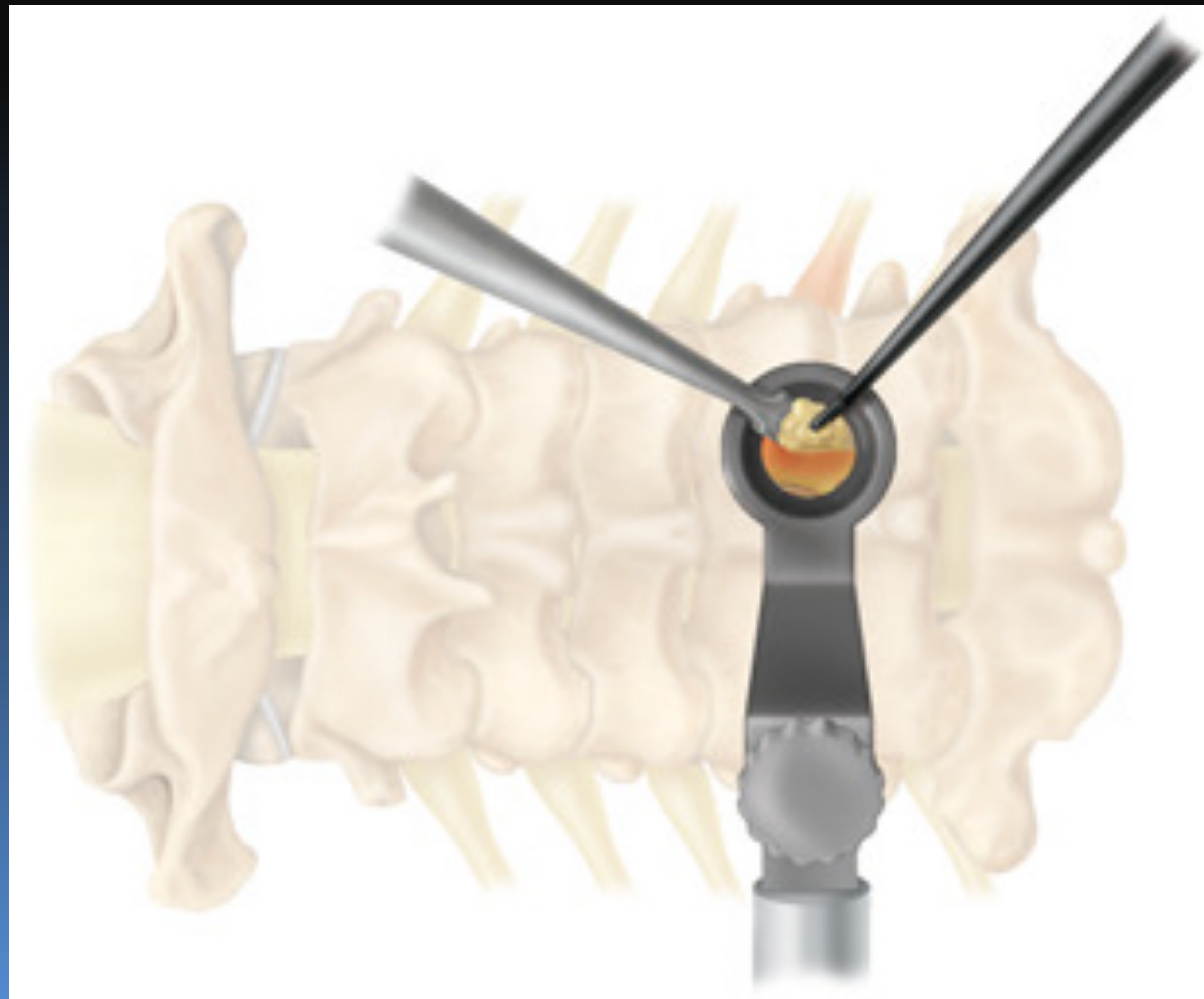
**Endoscopic spine surgery center, Neurosurgery**  
**Chundam Harrison Hospital, Seoul, South Korea**

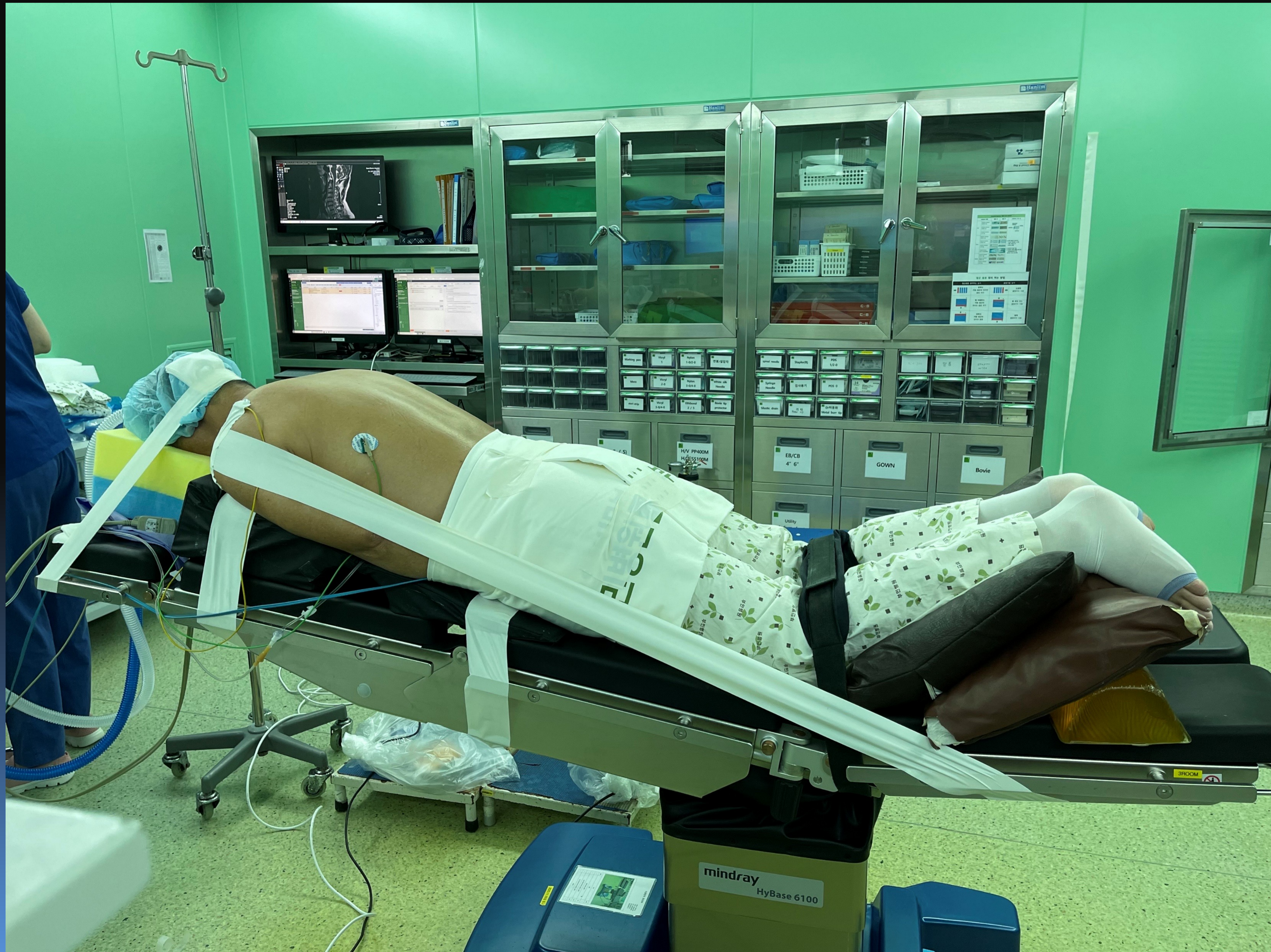# Post. Cervical foraminotomy by UBE

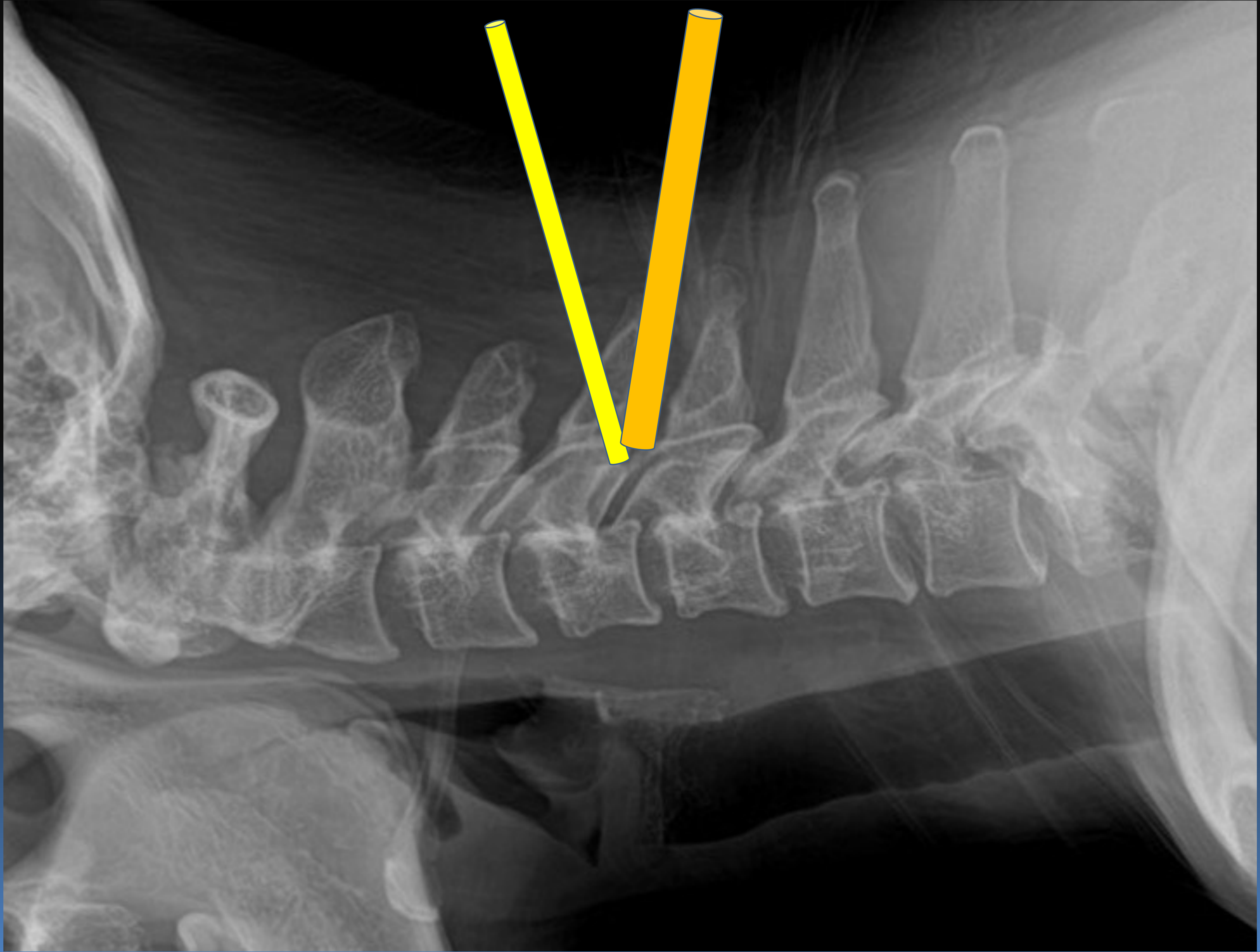
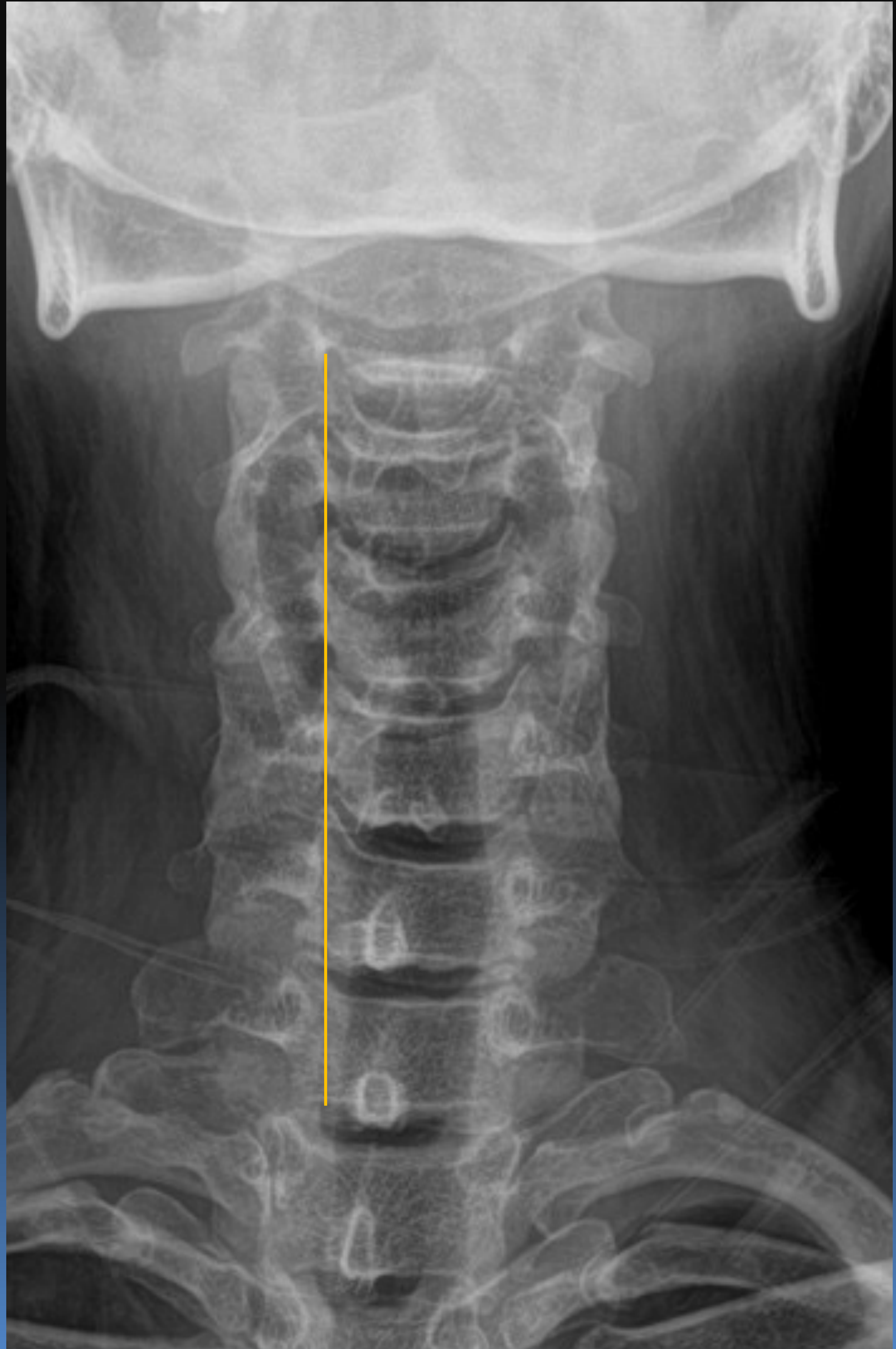@ Biportal Endoscopic cervical posterior foraminotomy

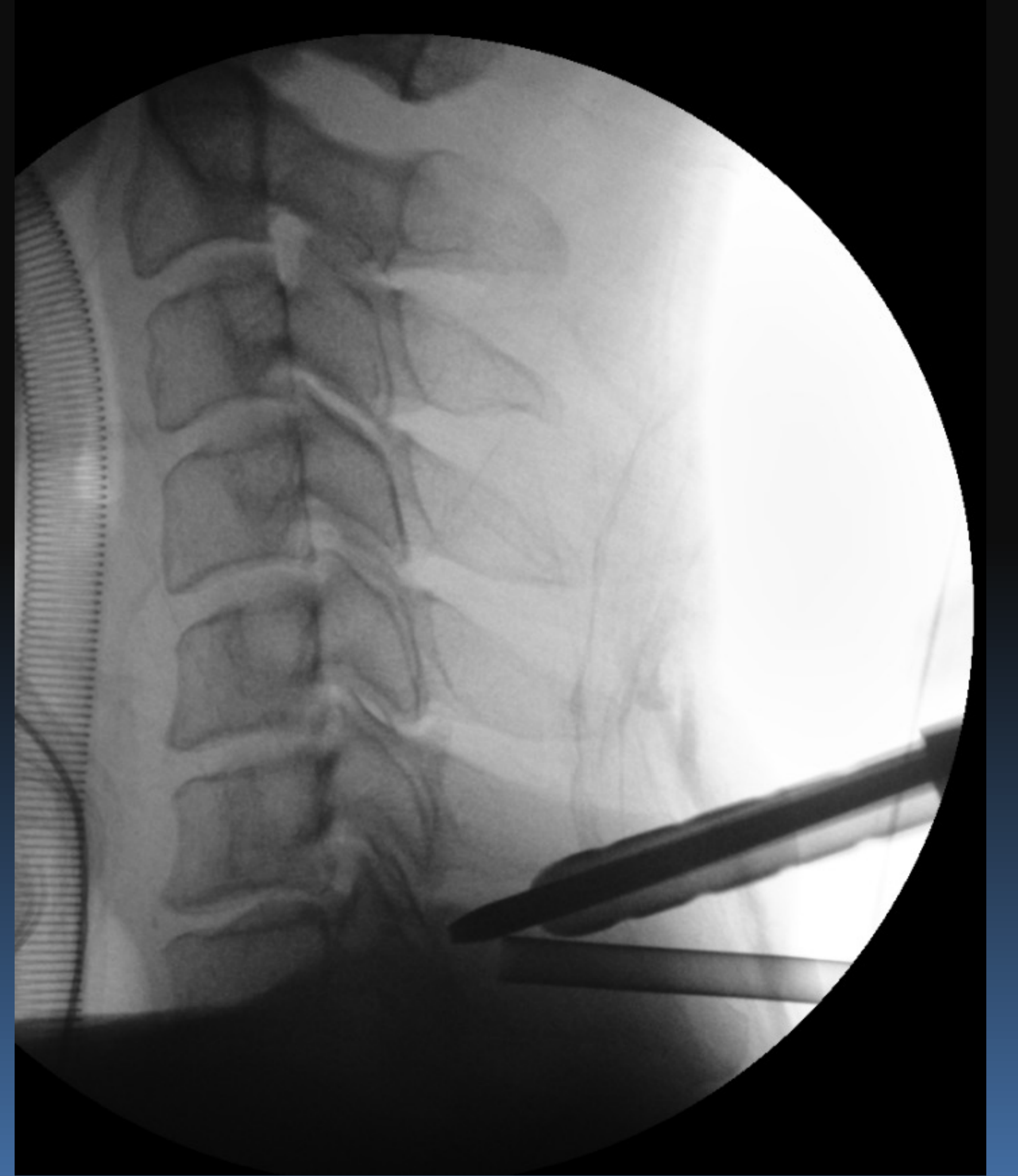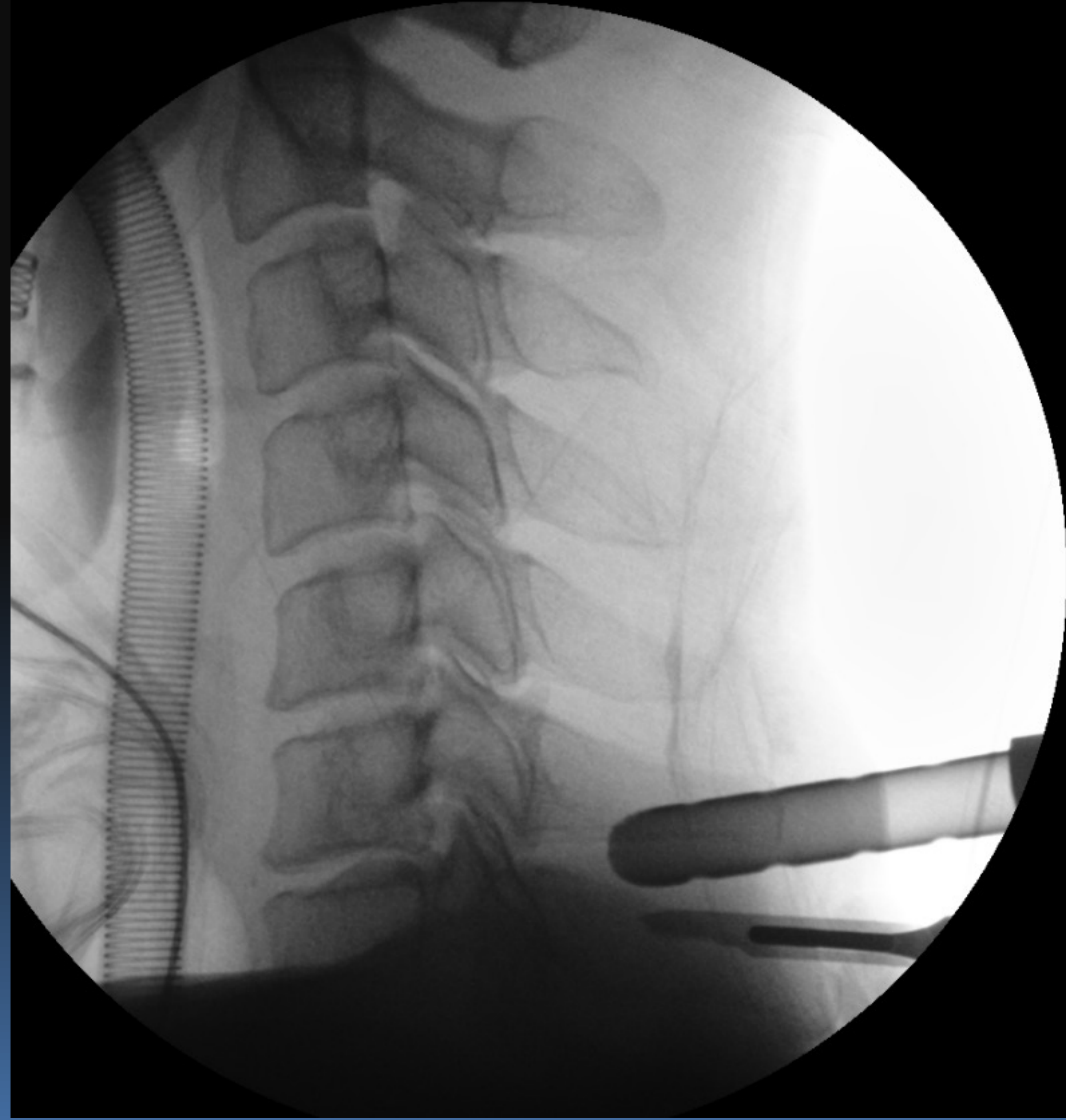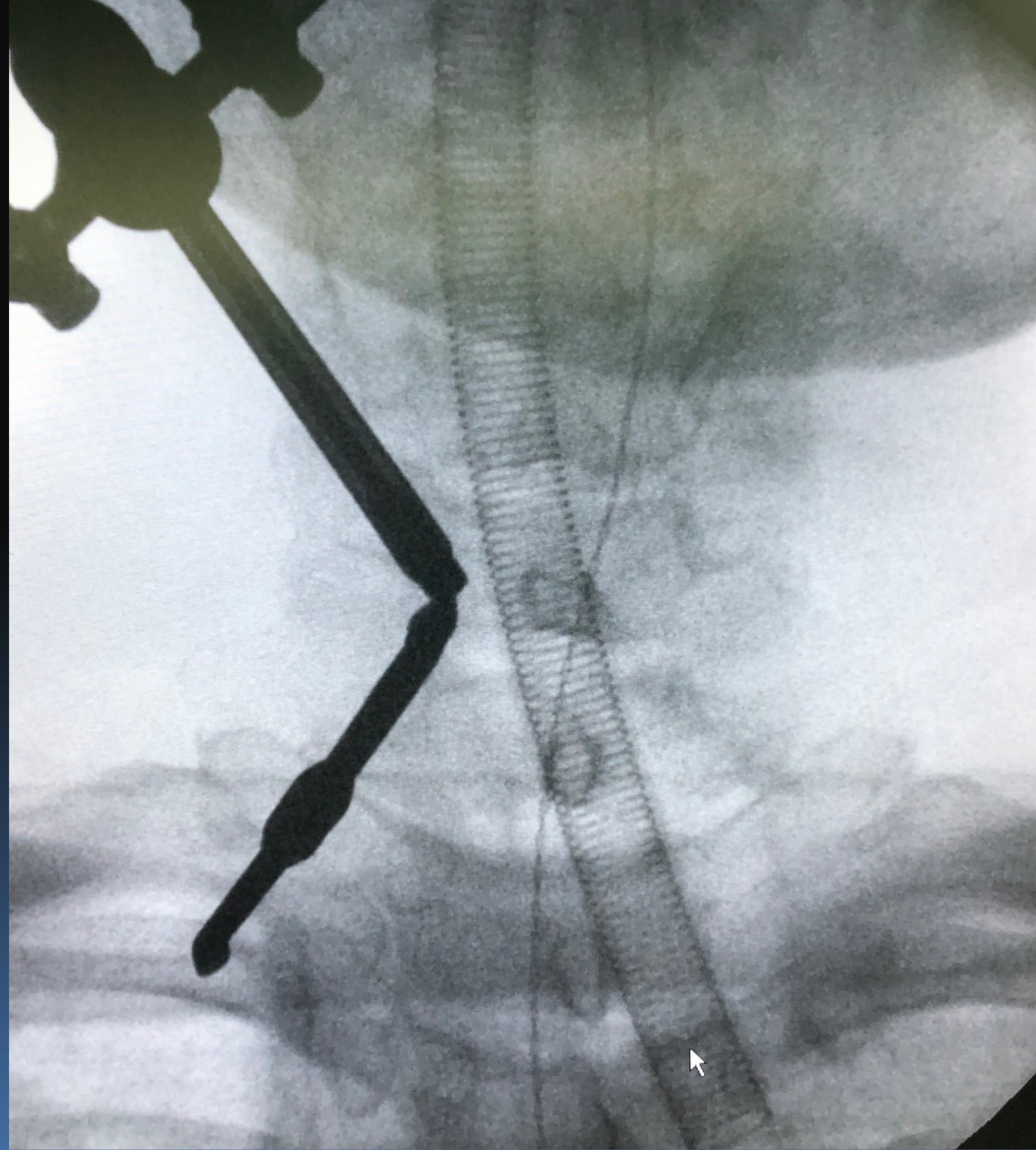
**Similar to** Microscopic posterior cervical foraminotomy

using **tubular retractor systems**

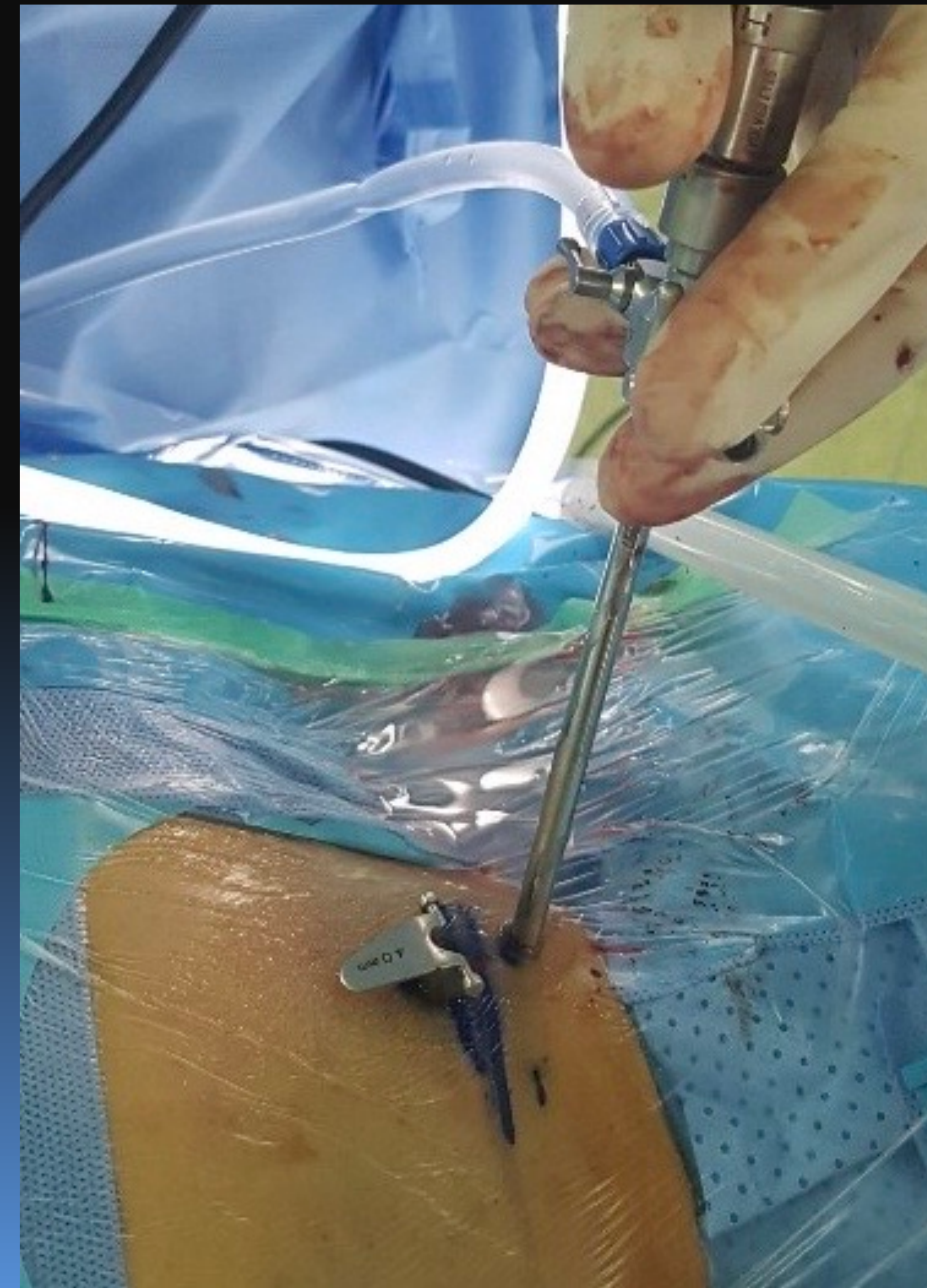
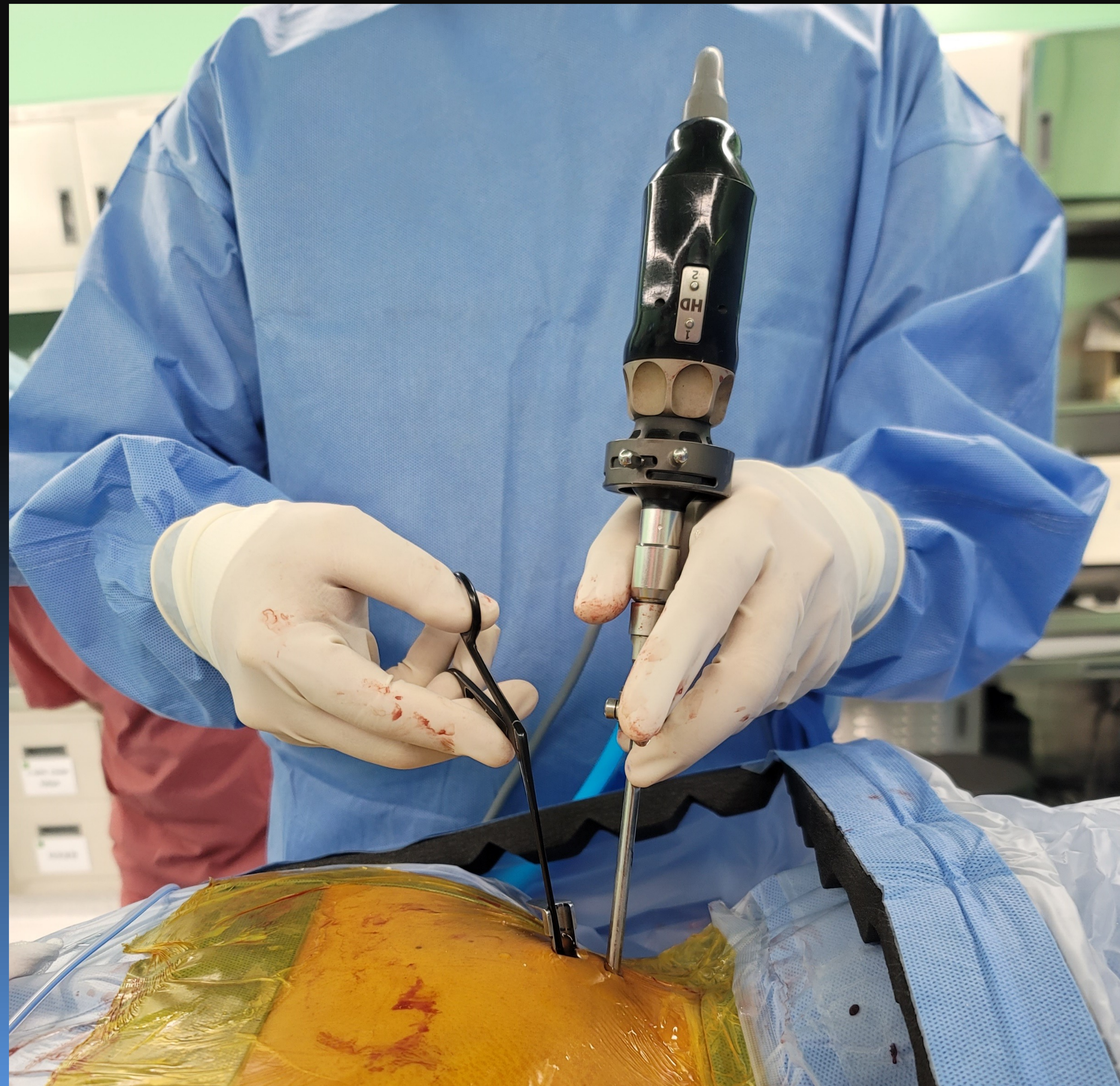



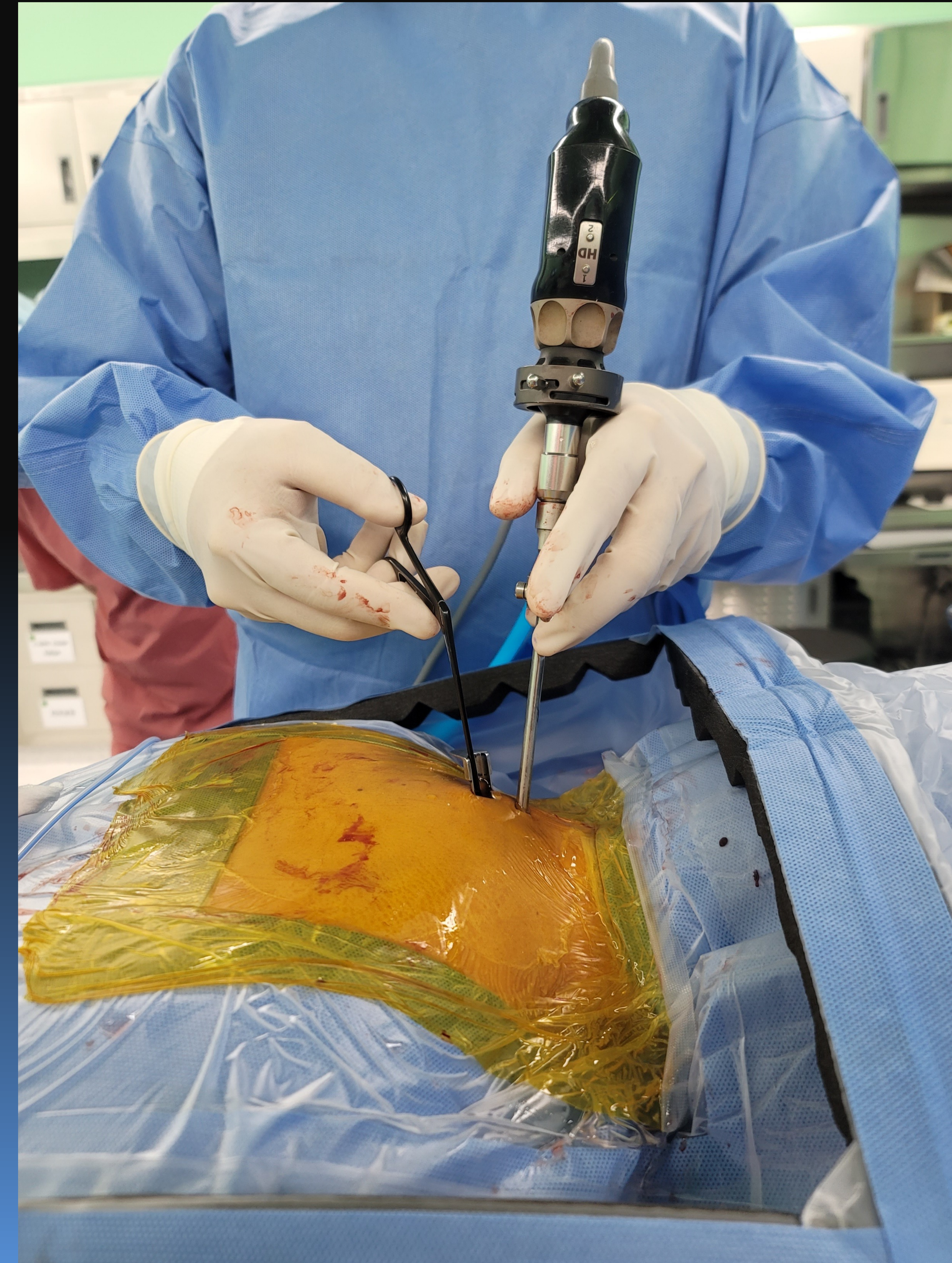

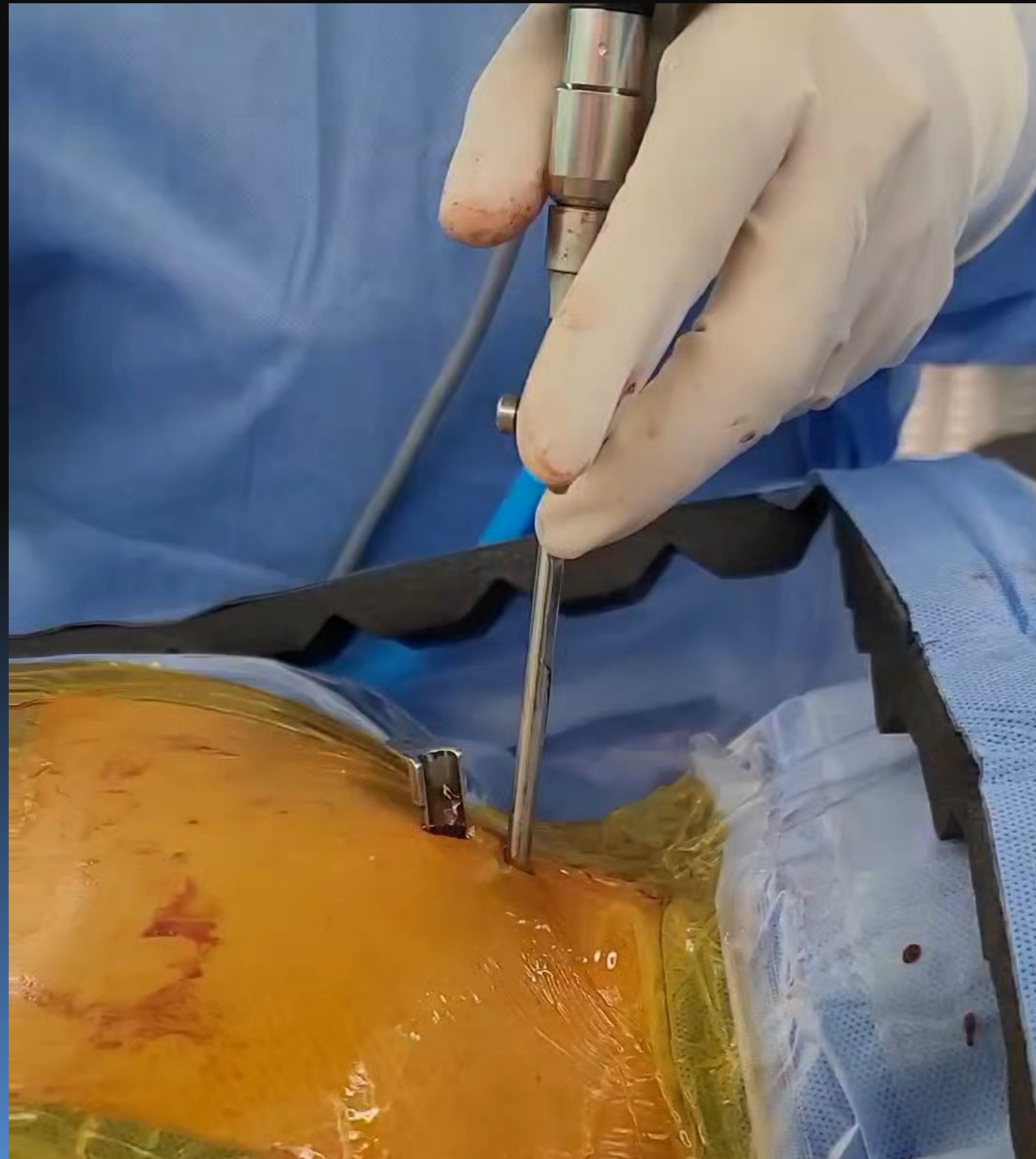


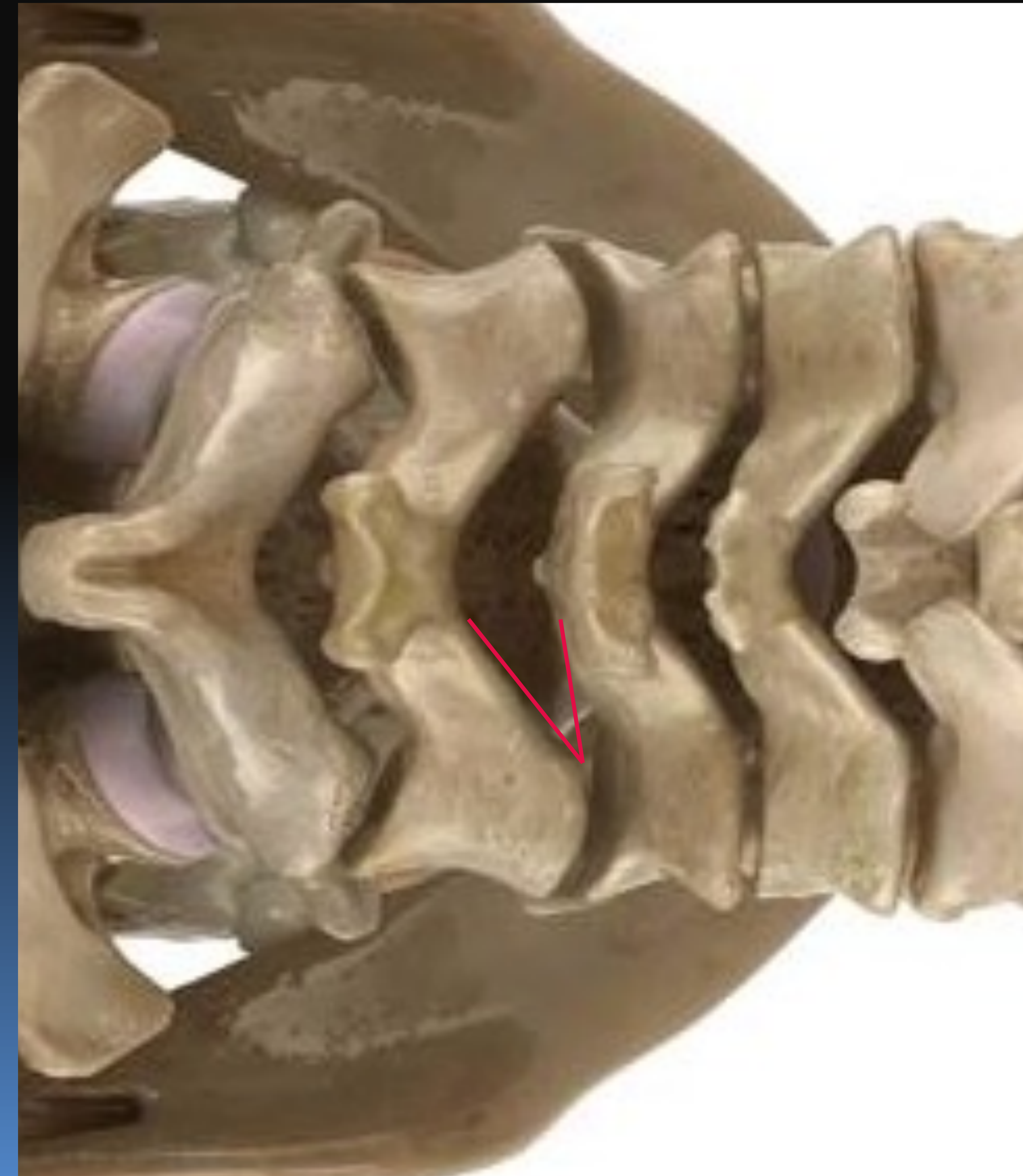
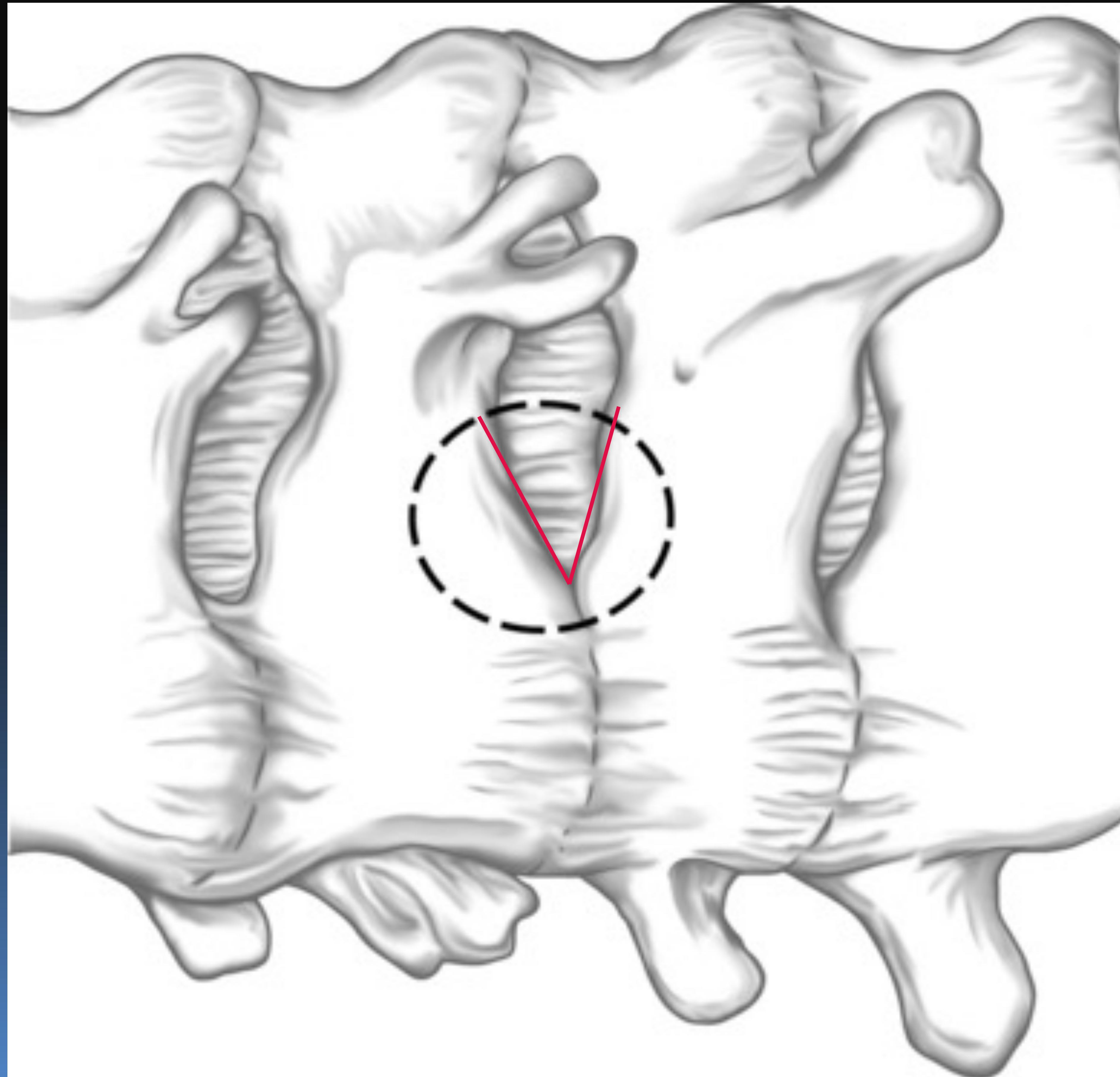
# Overview of Biportal Endoscopic PCF



**The irrigation fluid must be well drained.**



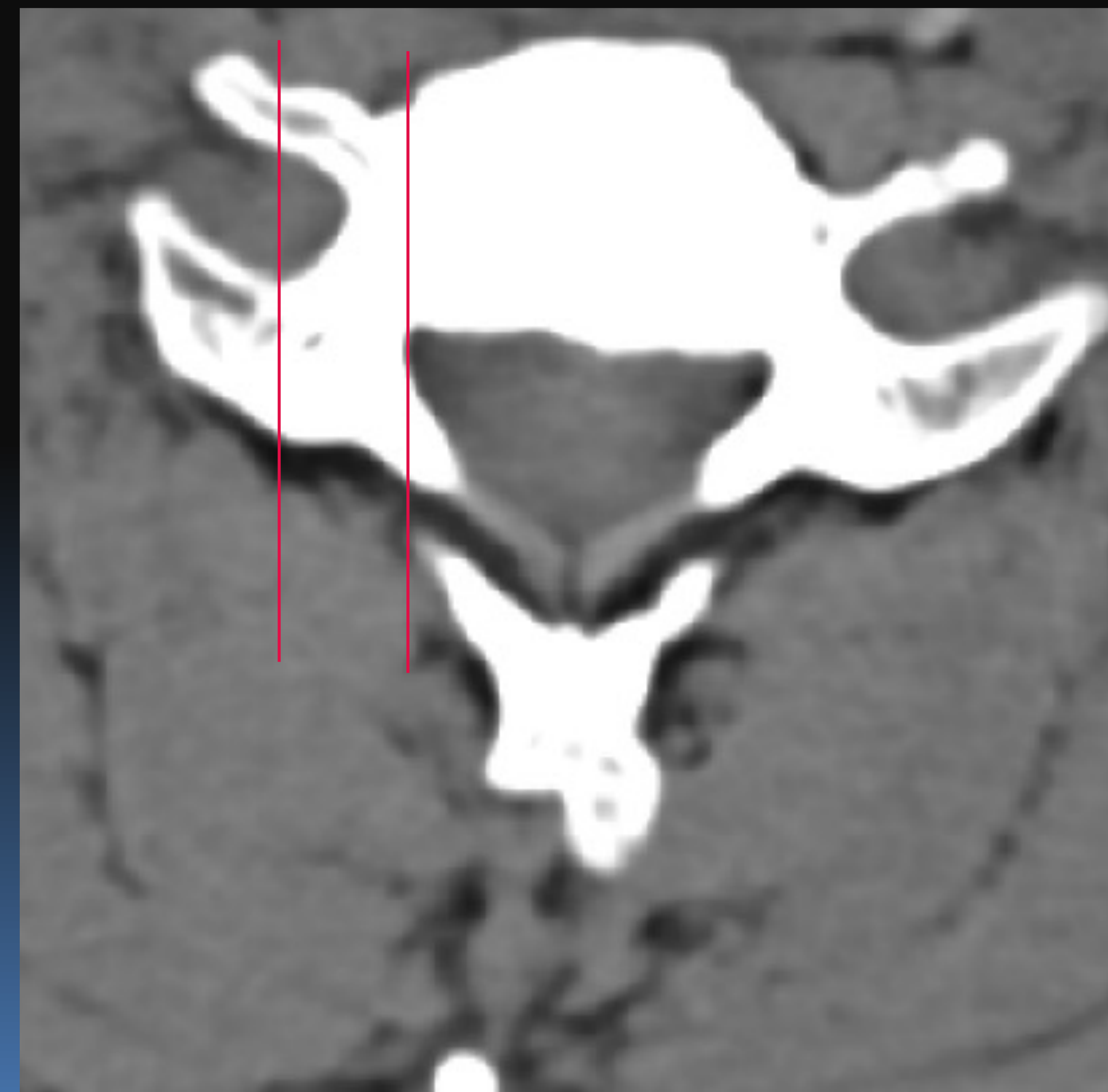
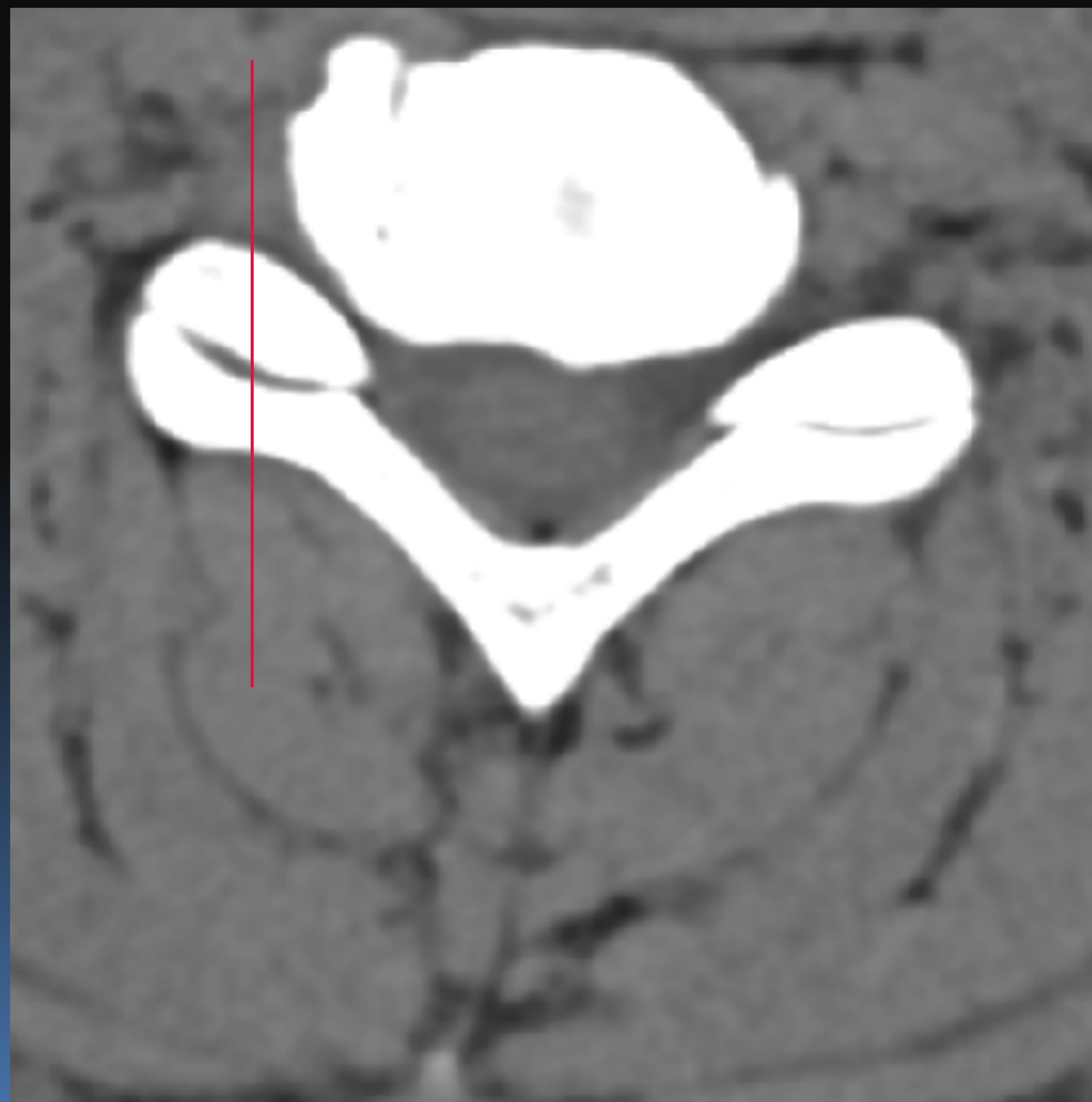
# Dissection and Check “V point”

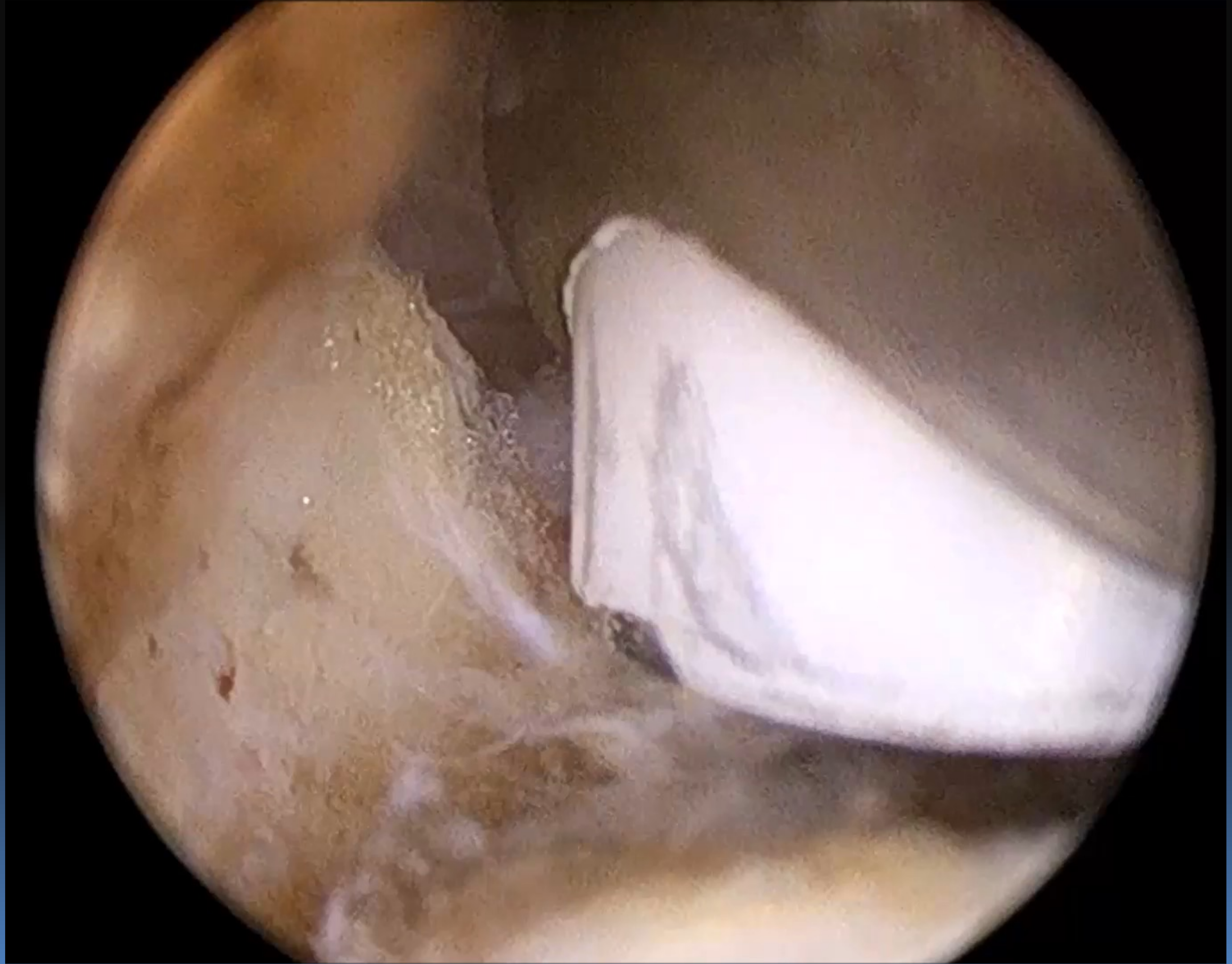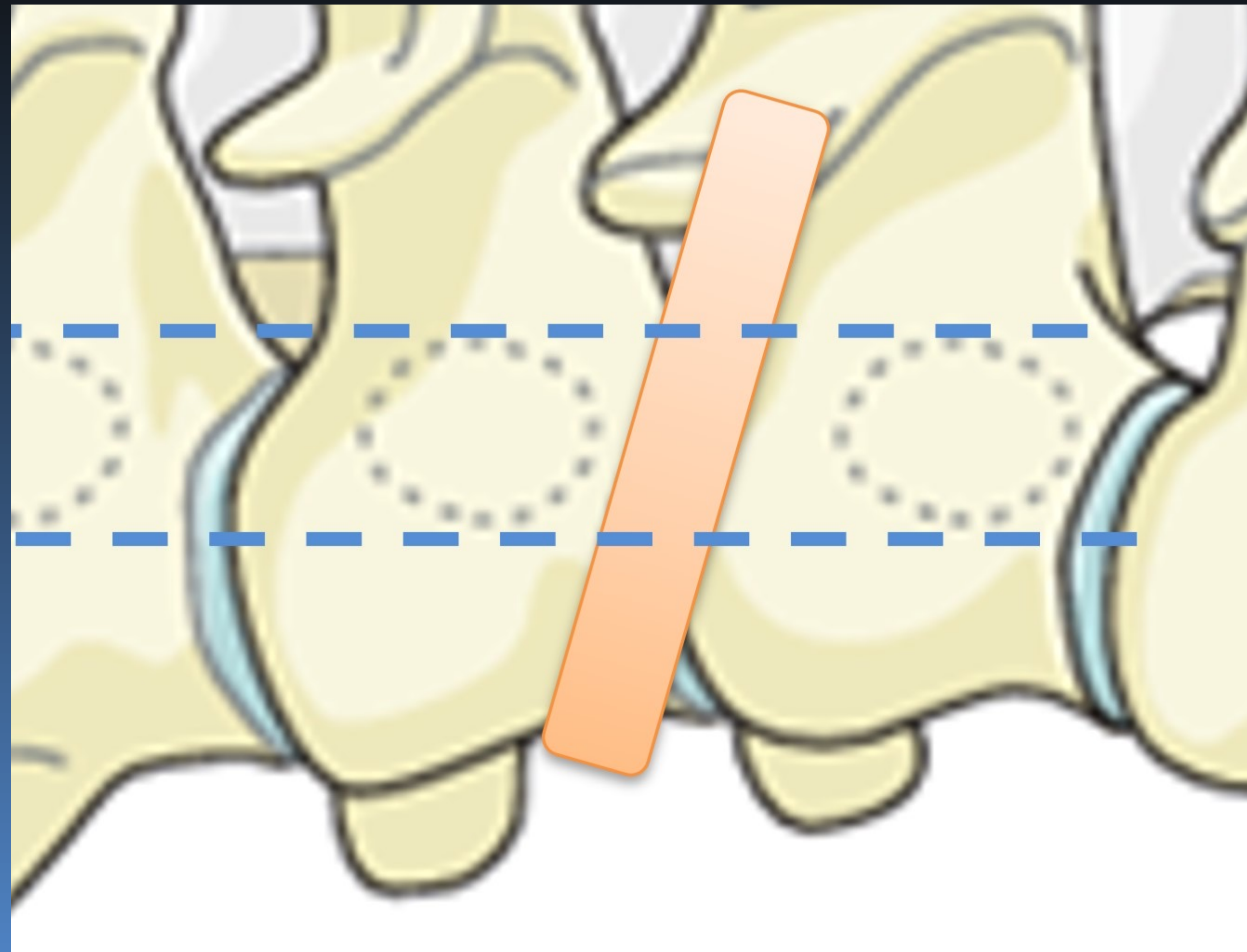
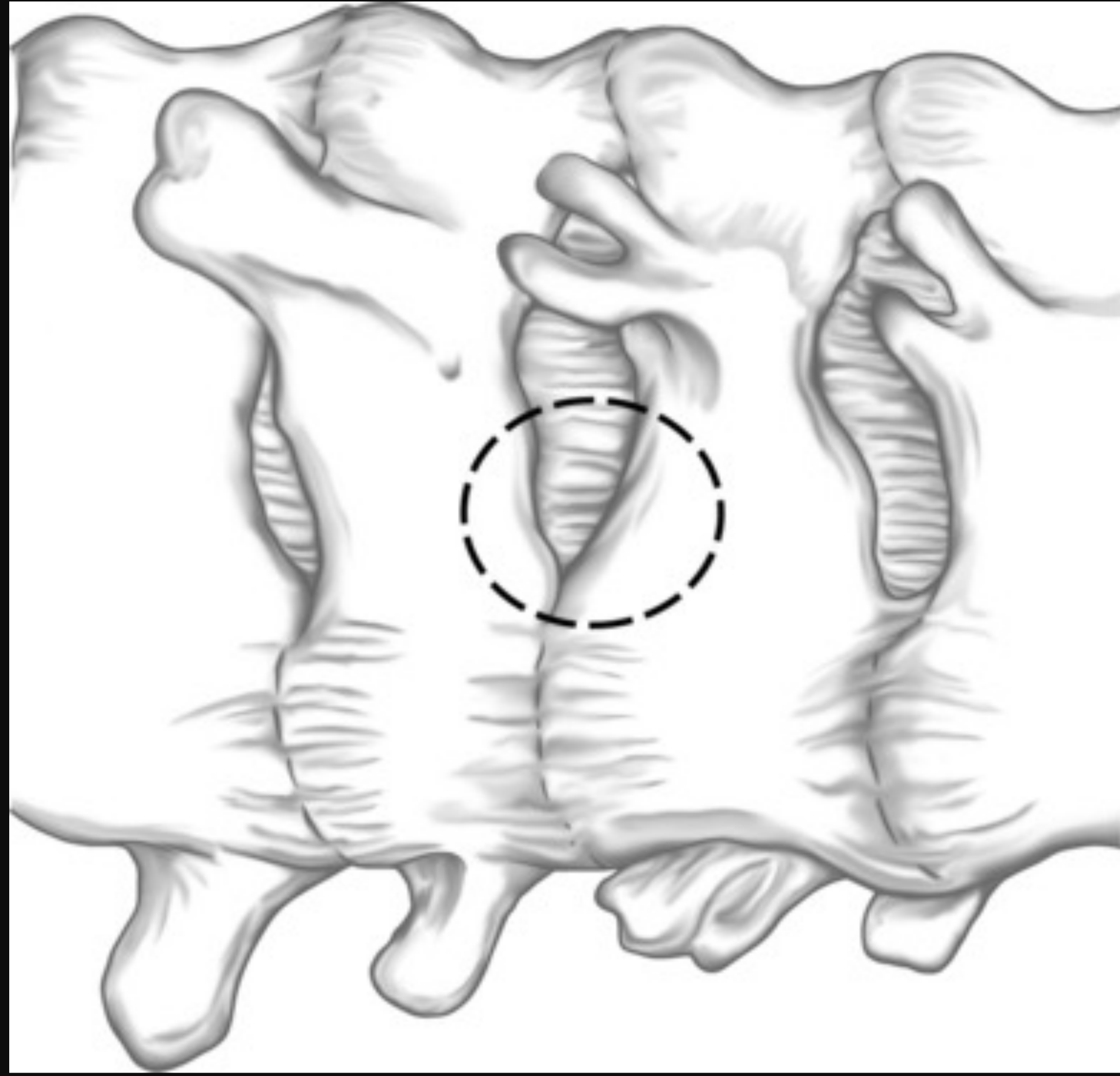




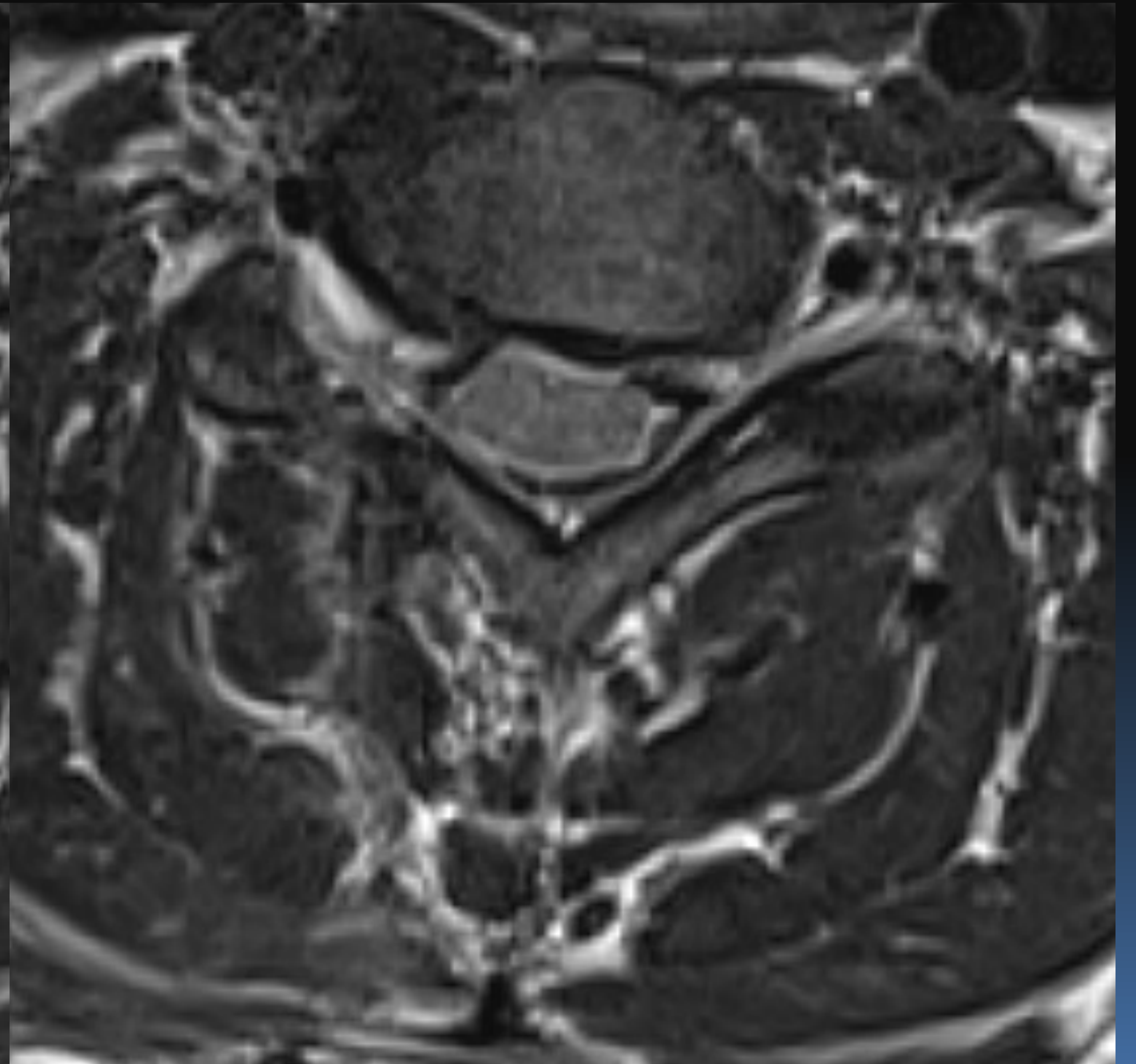
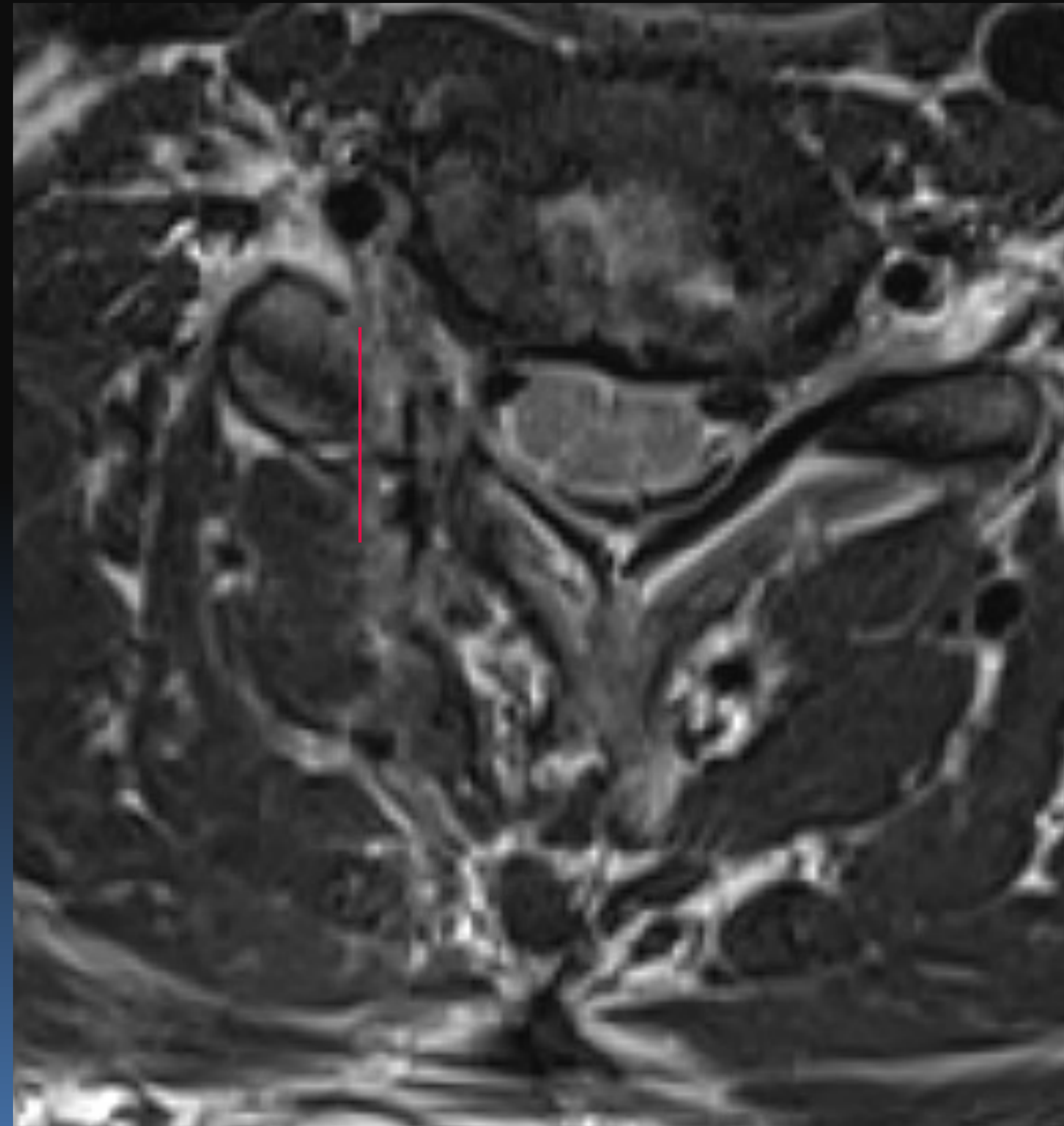
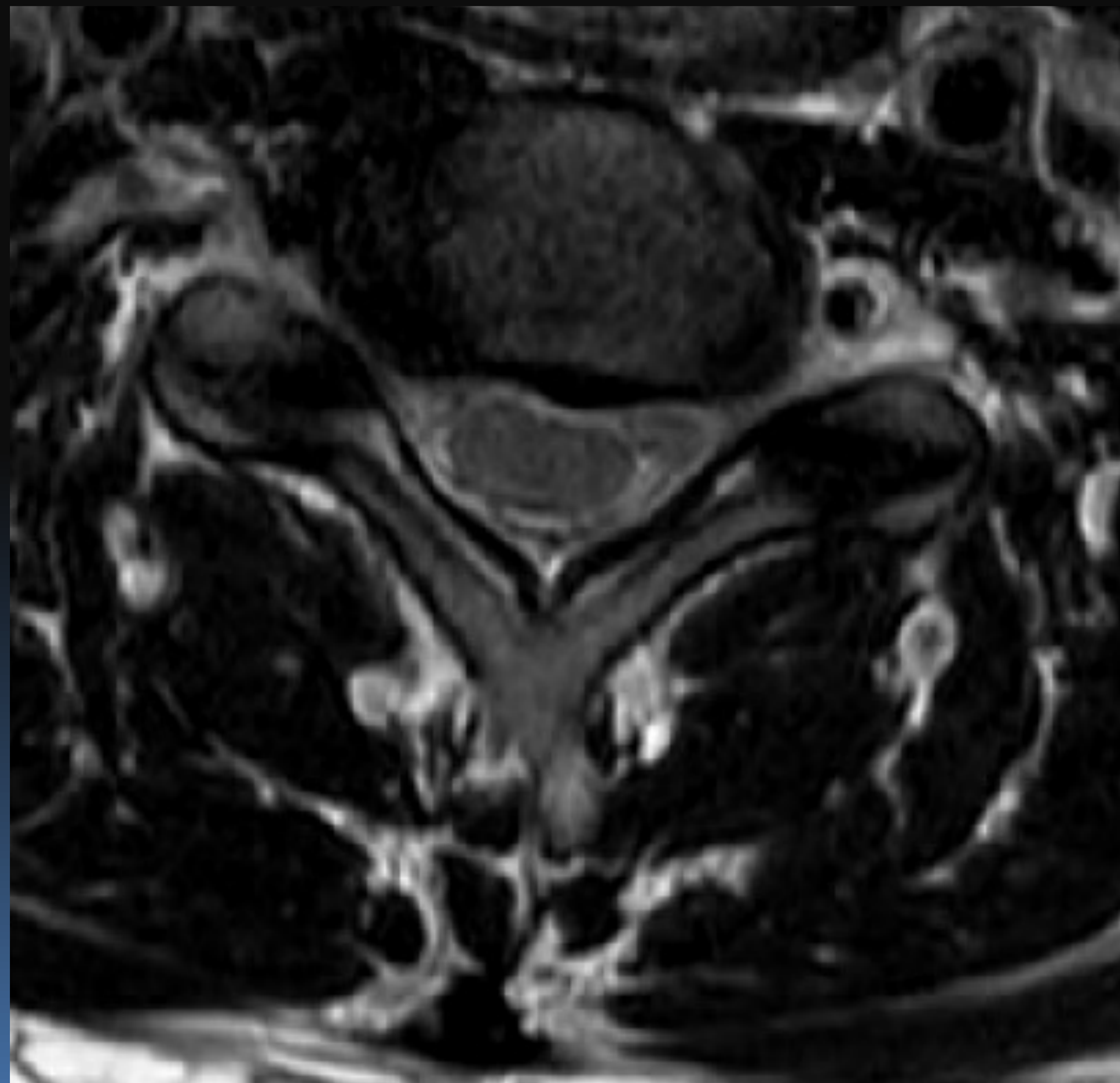
**Foraminotomy; From pedicle to pedicle**

**From pedicle medial to lateral border, About 50 % facet**

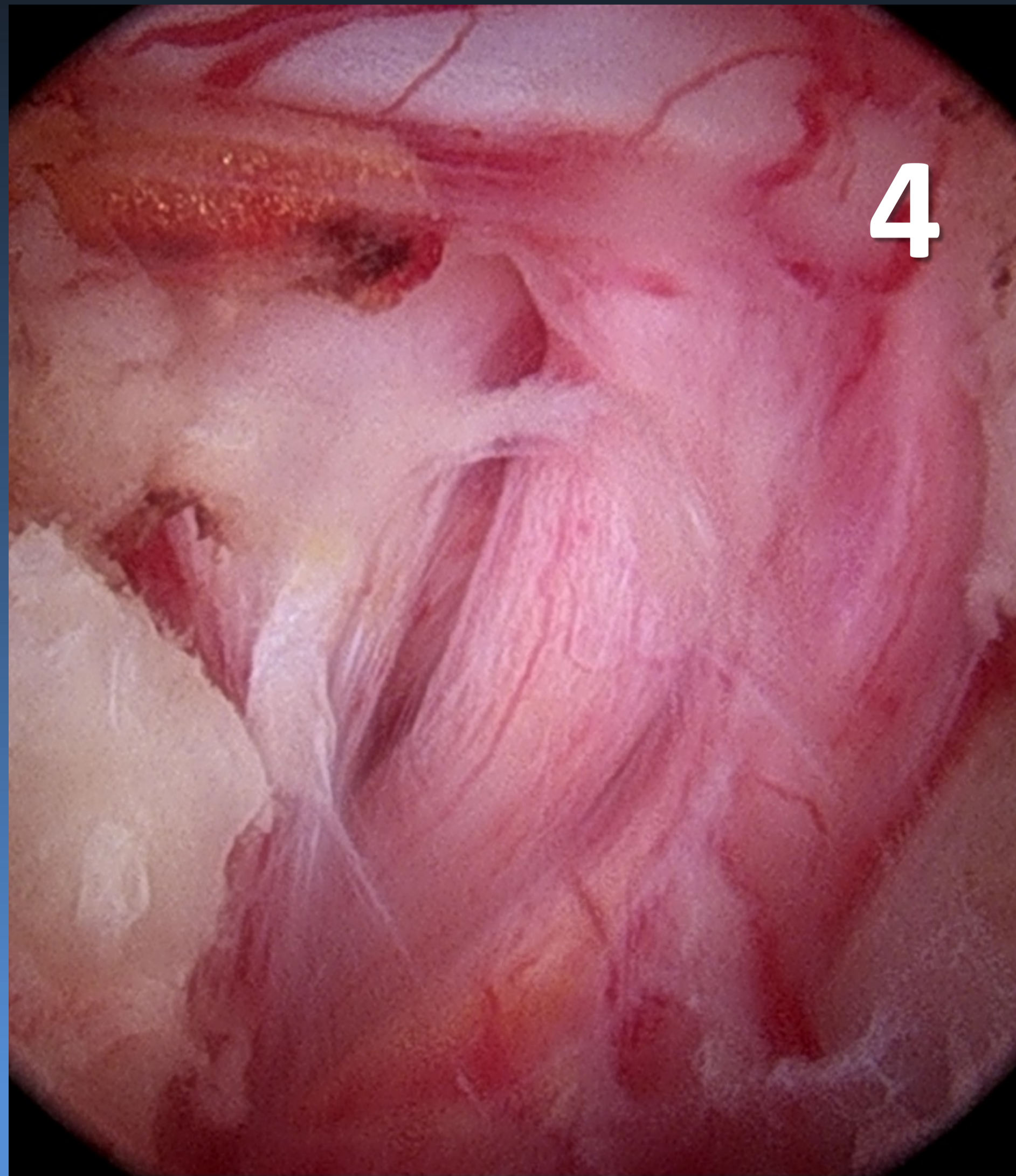
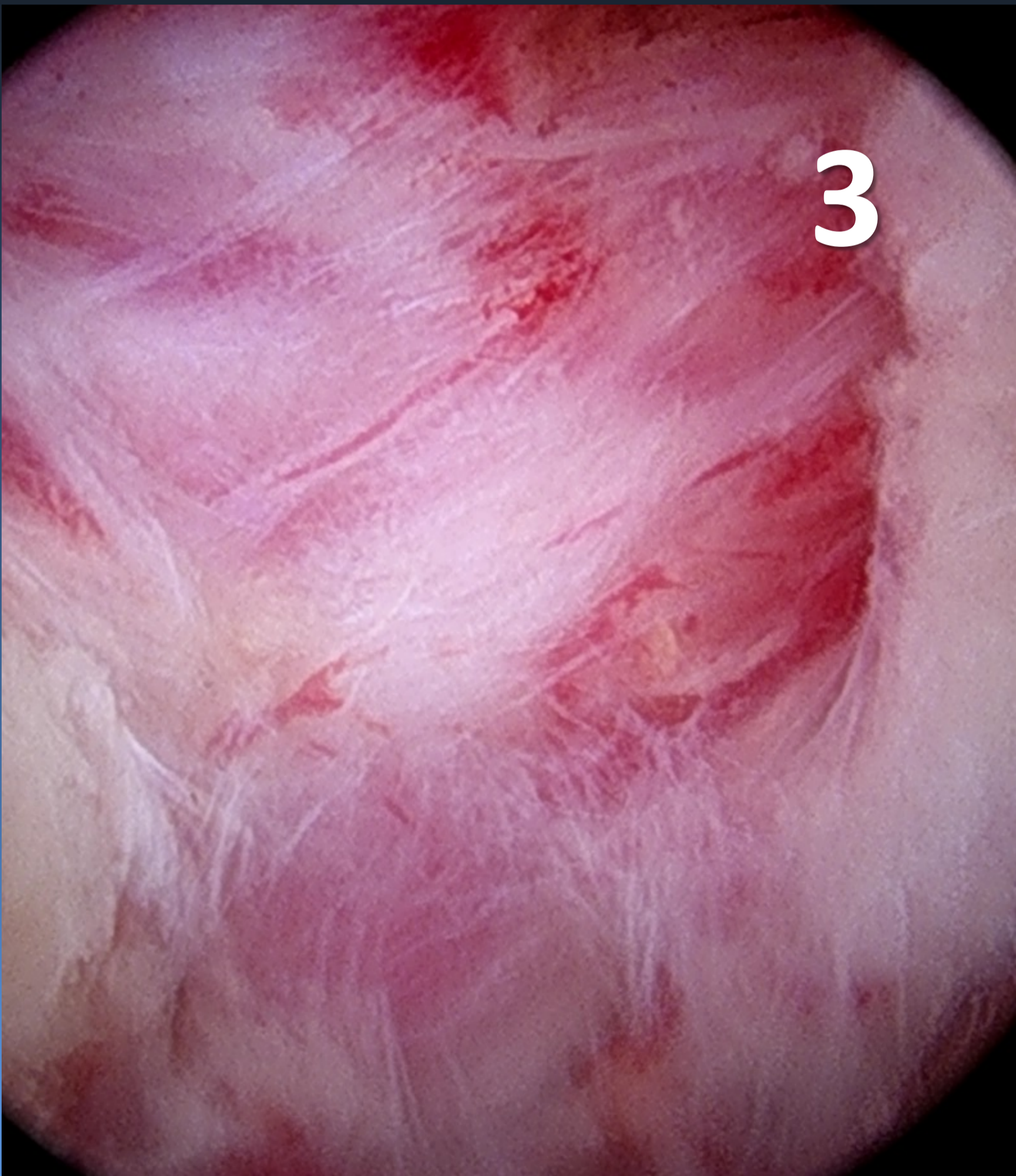
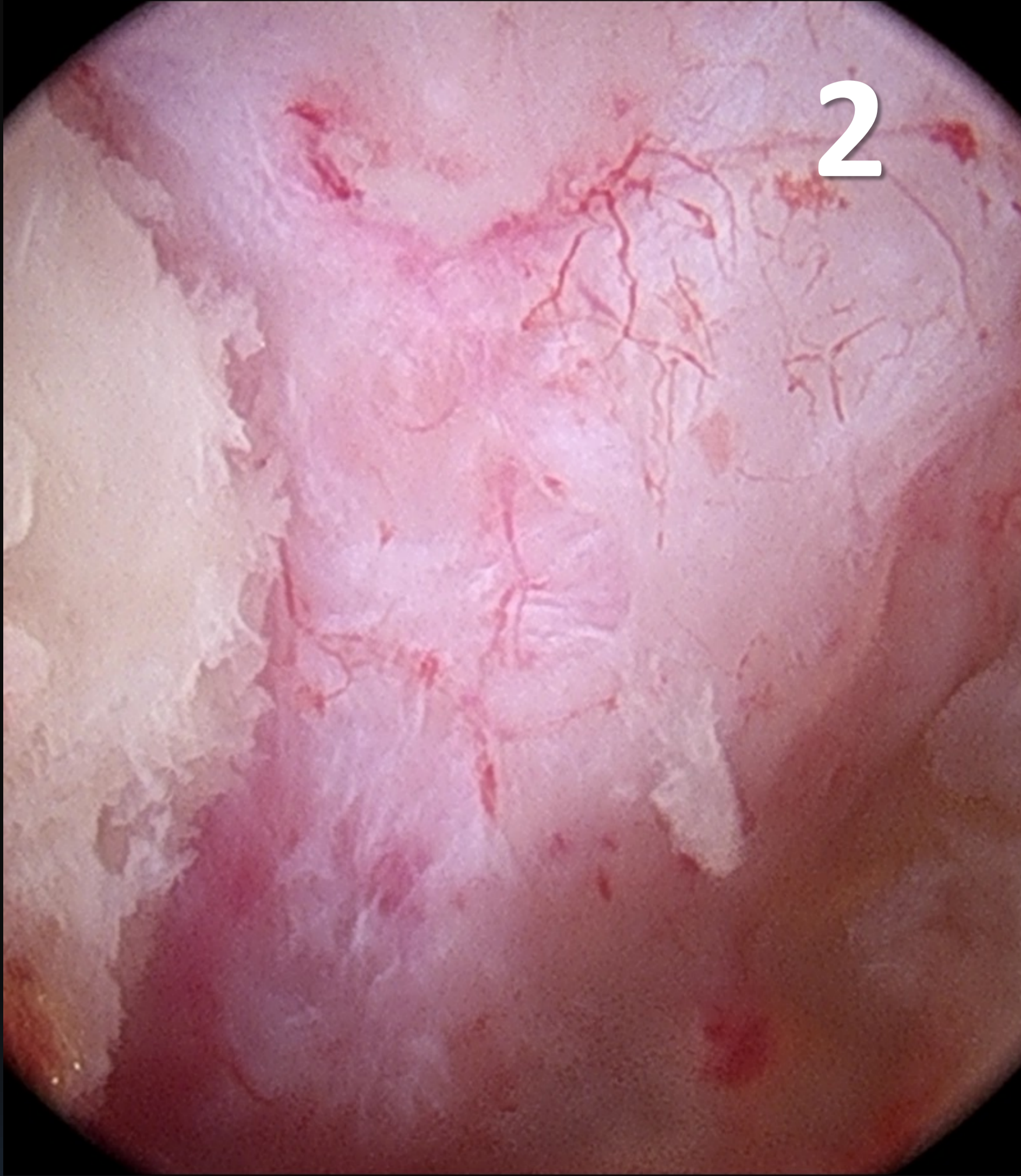
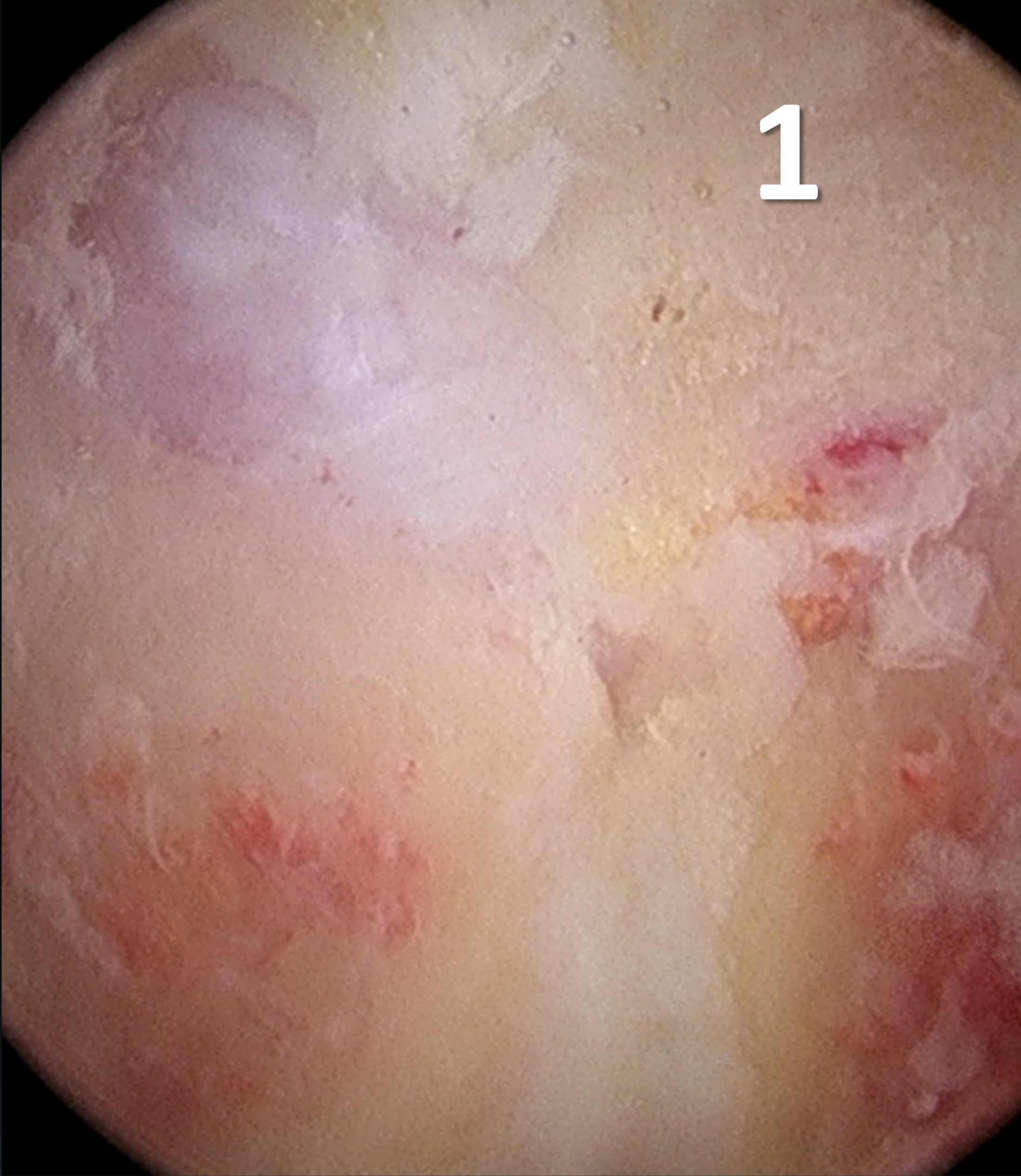
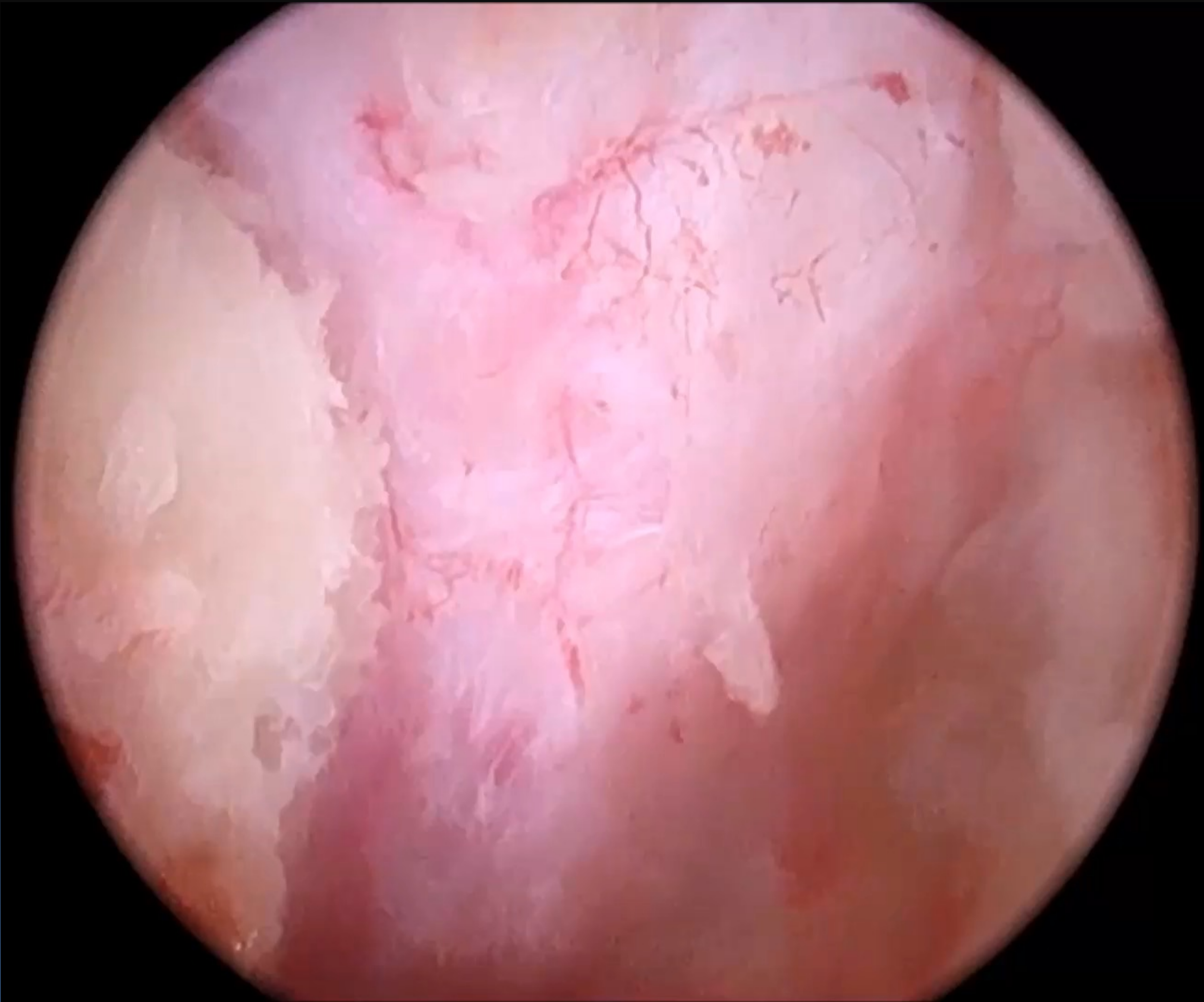




**44/M Rt arm and hand tingling and radiating pain C 56**

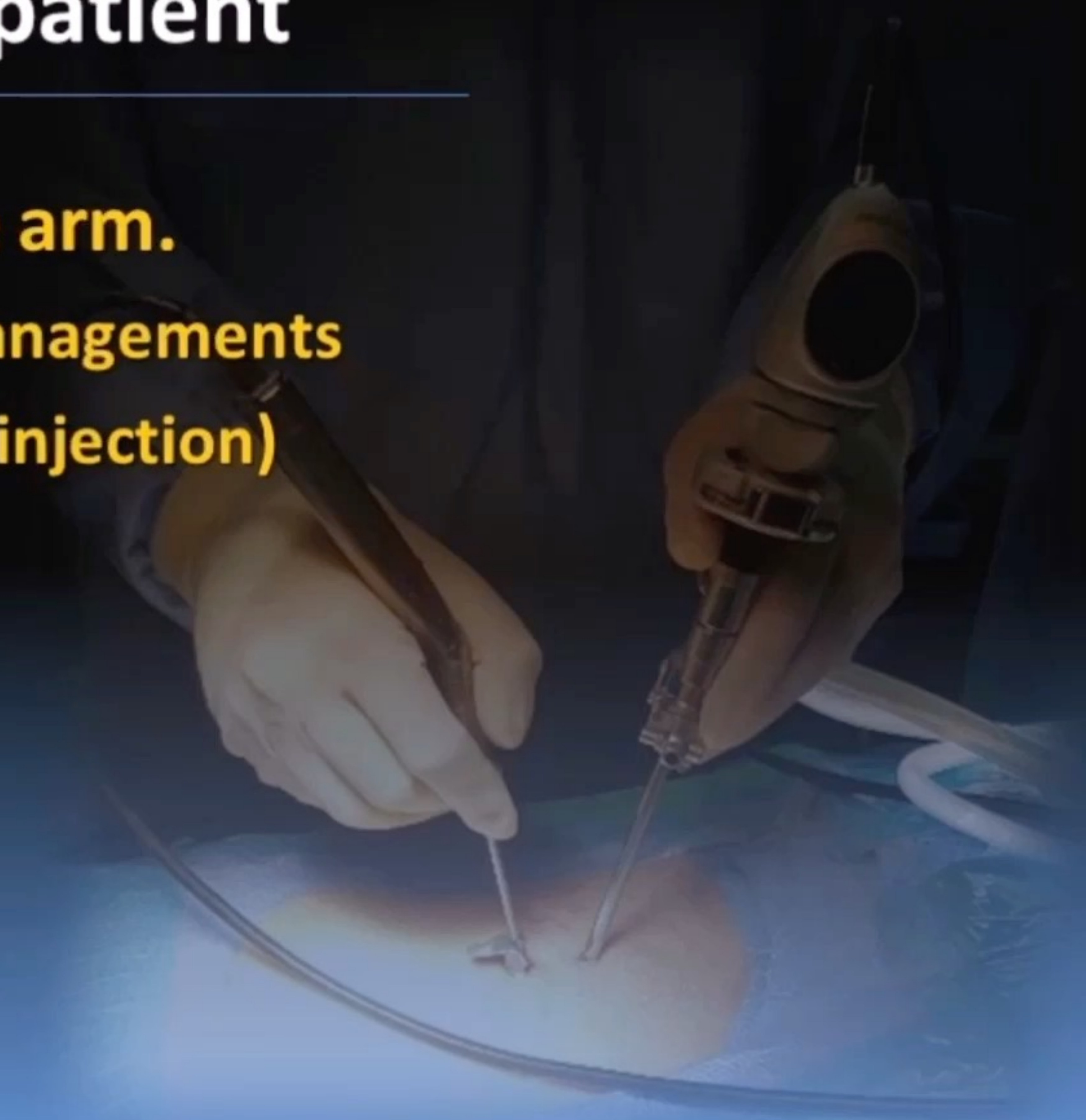


**Posterior epidural membrane. Fibro-areolar tissue:  
adhere with cervical nerve root**



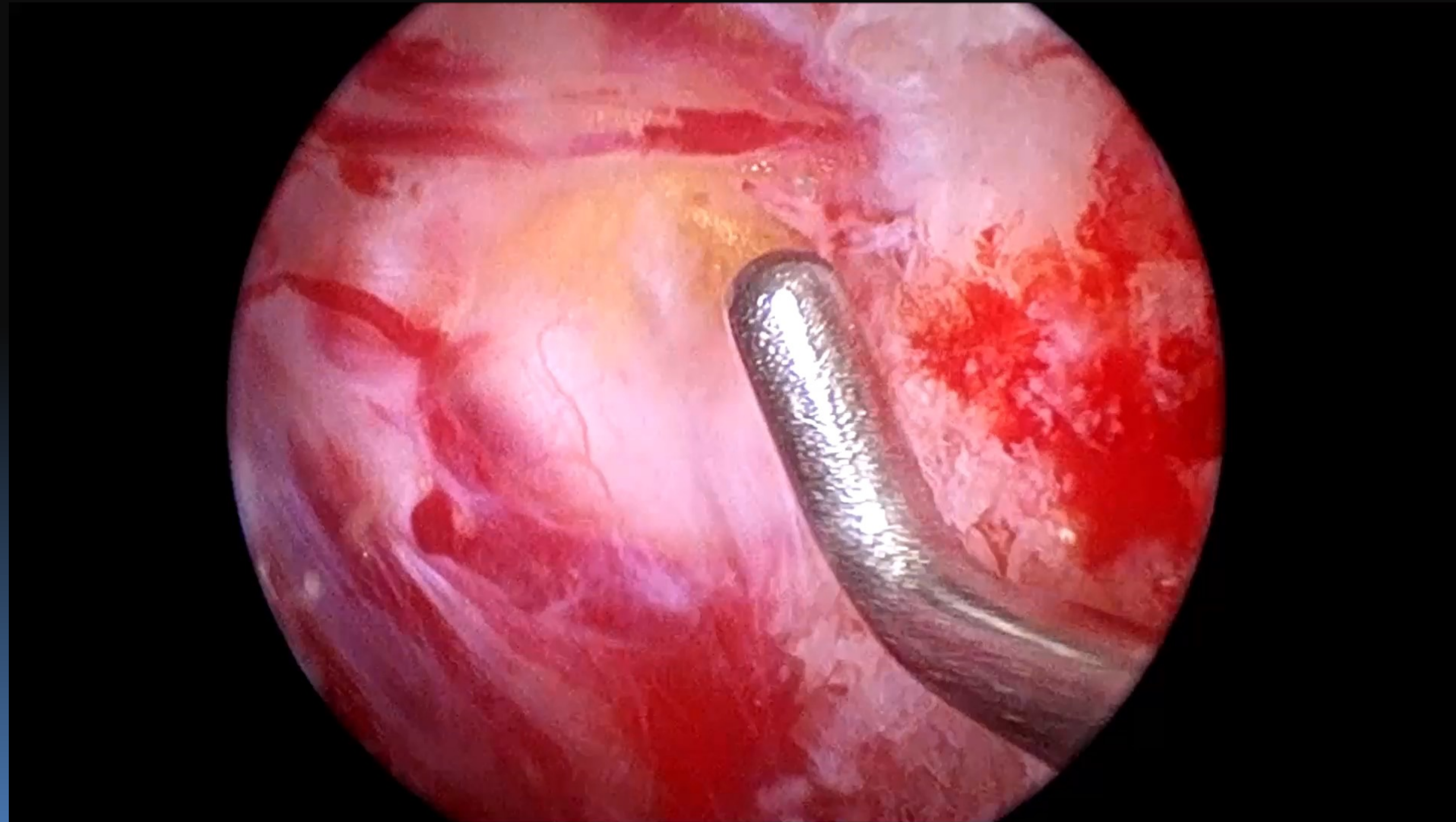
## 40 years old male patient

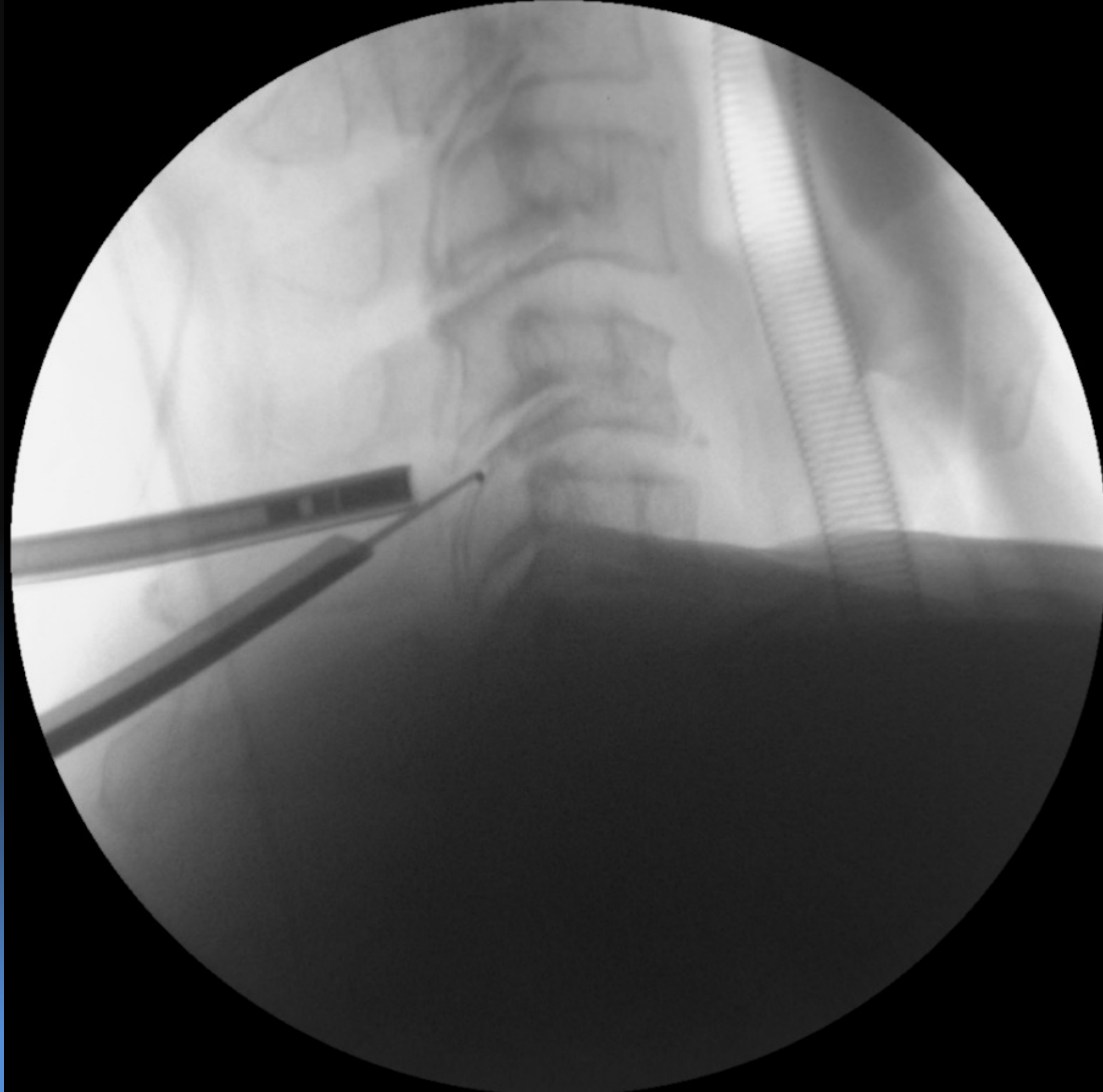
- **Severe radicular pain of right-side arm.**  
Refractory pain to conservative managements  
(including epidural injection)
- **Neurological Examination**
  - Right C7 dermatome pain
  - DTR: decreased
  - Spurling sign: Positive
  - Hoffman sign: Negative

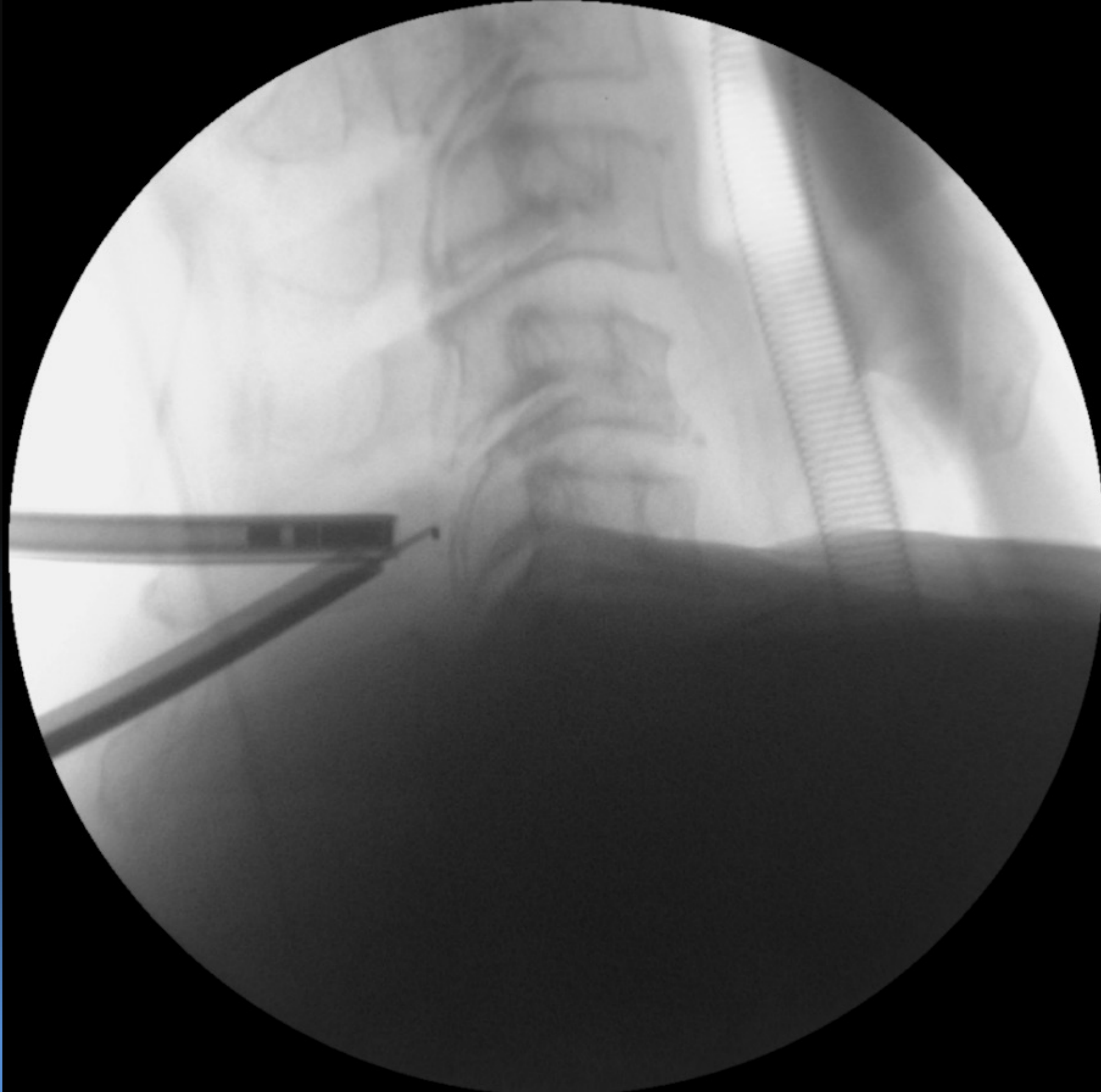


1. Case presentation

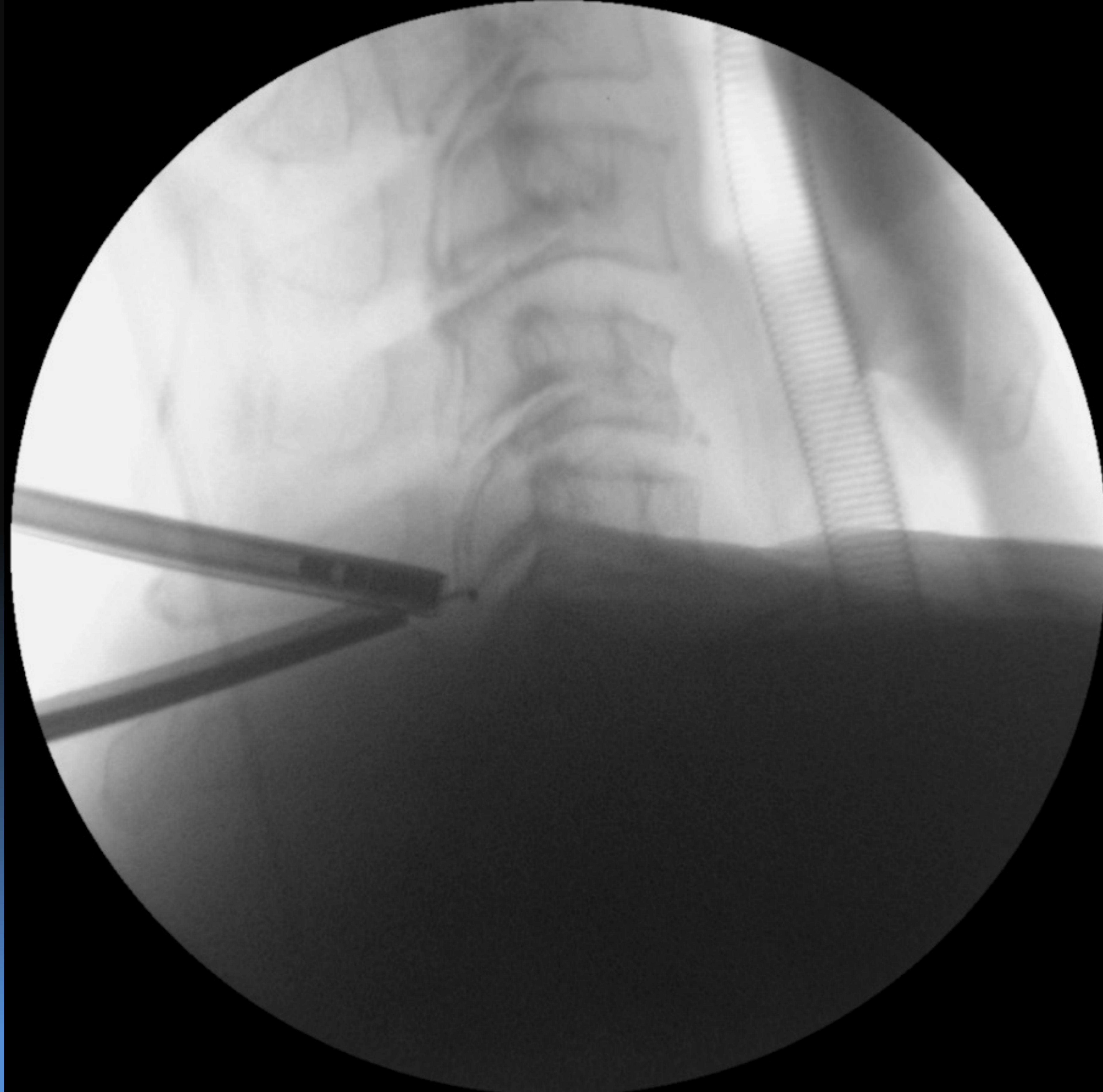
# Sliding technique: Two levels decompression by single approach

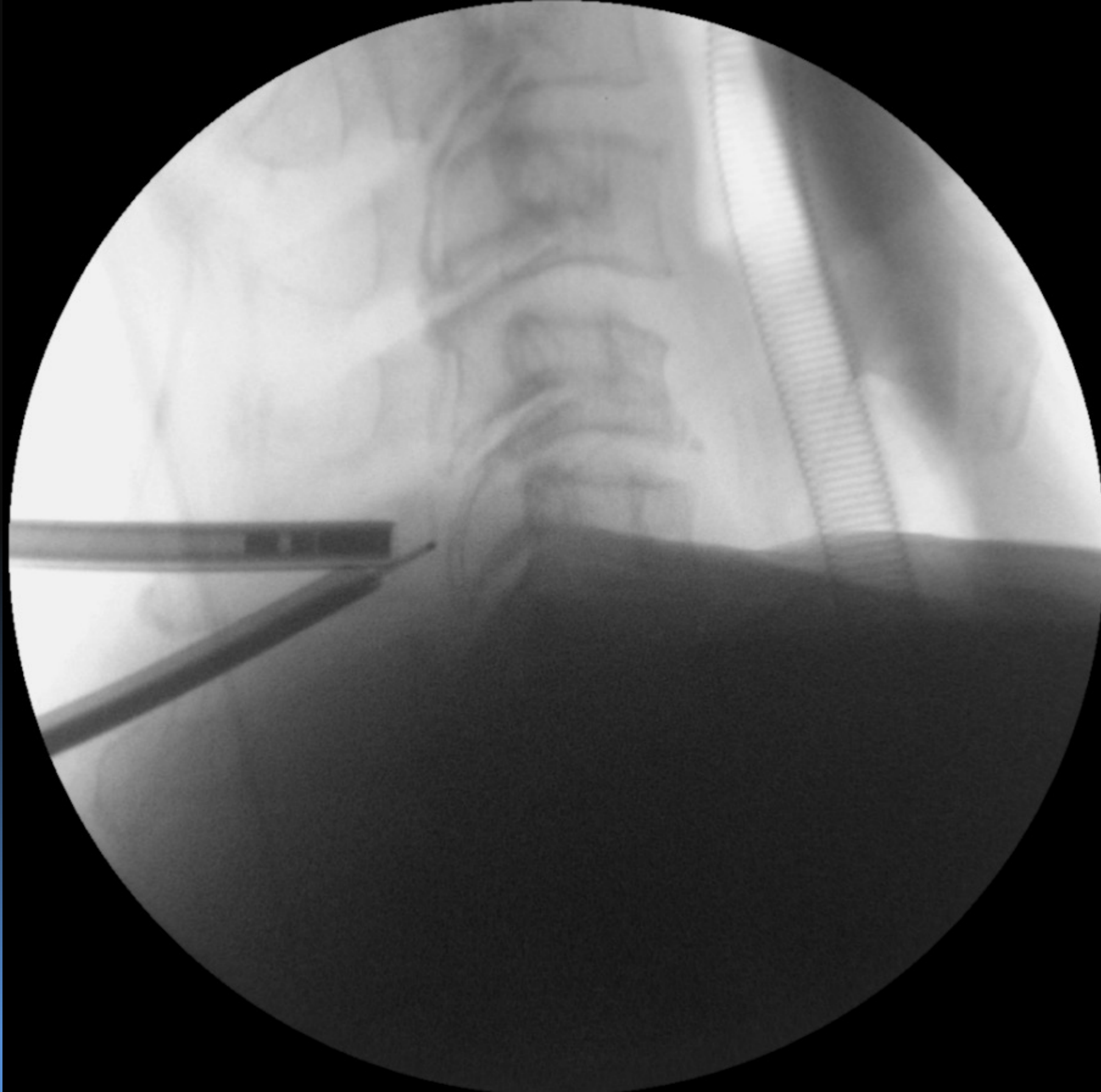


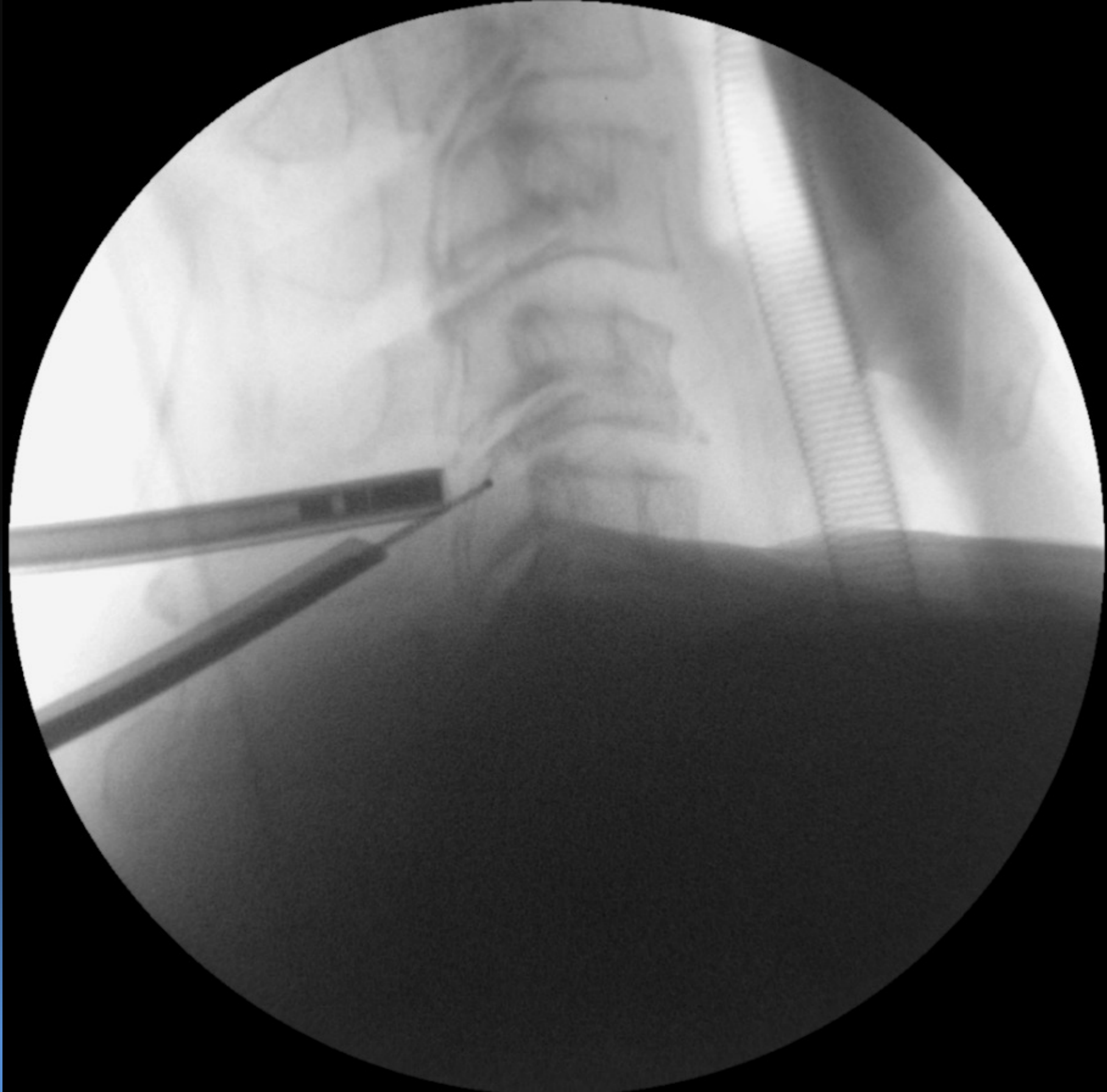



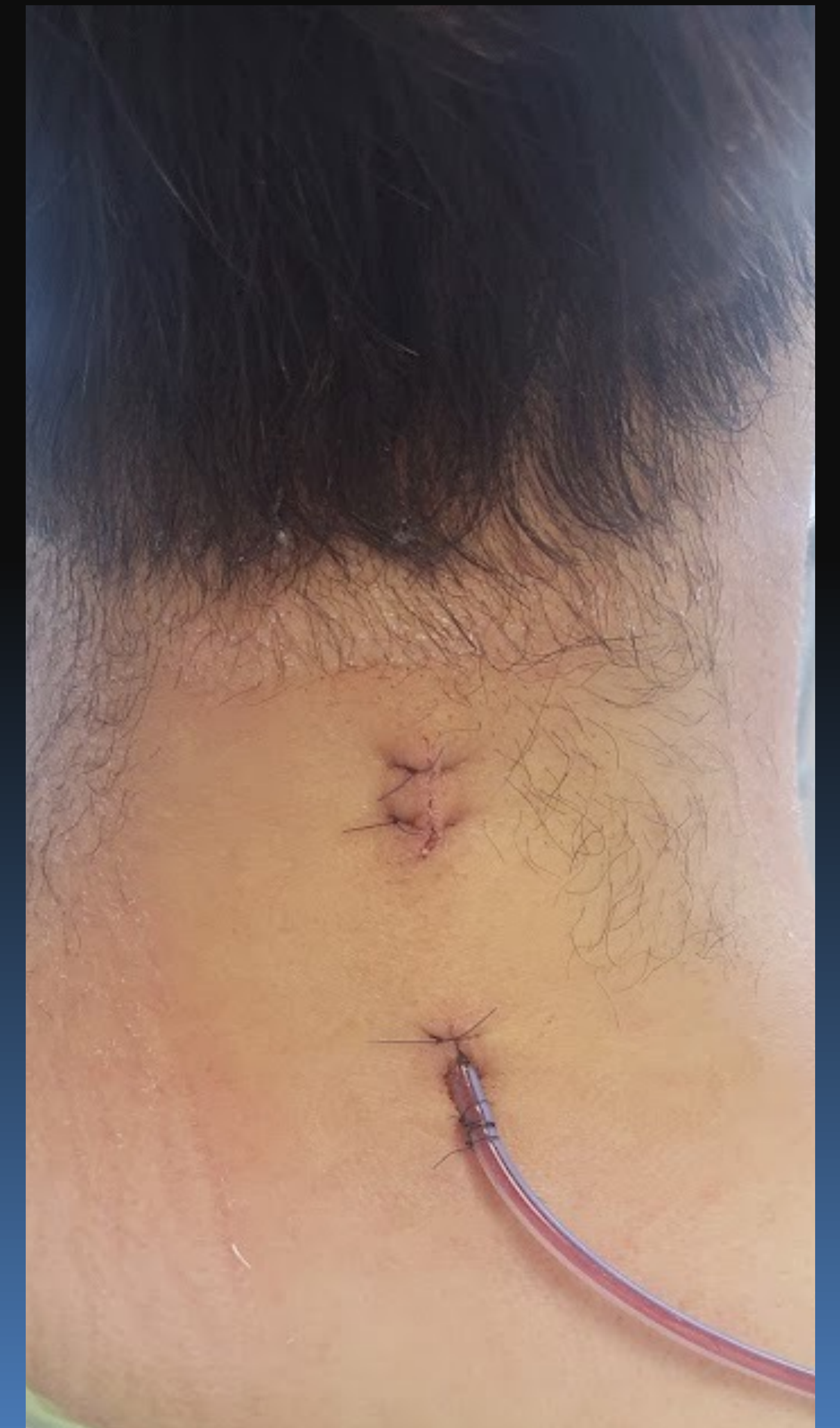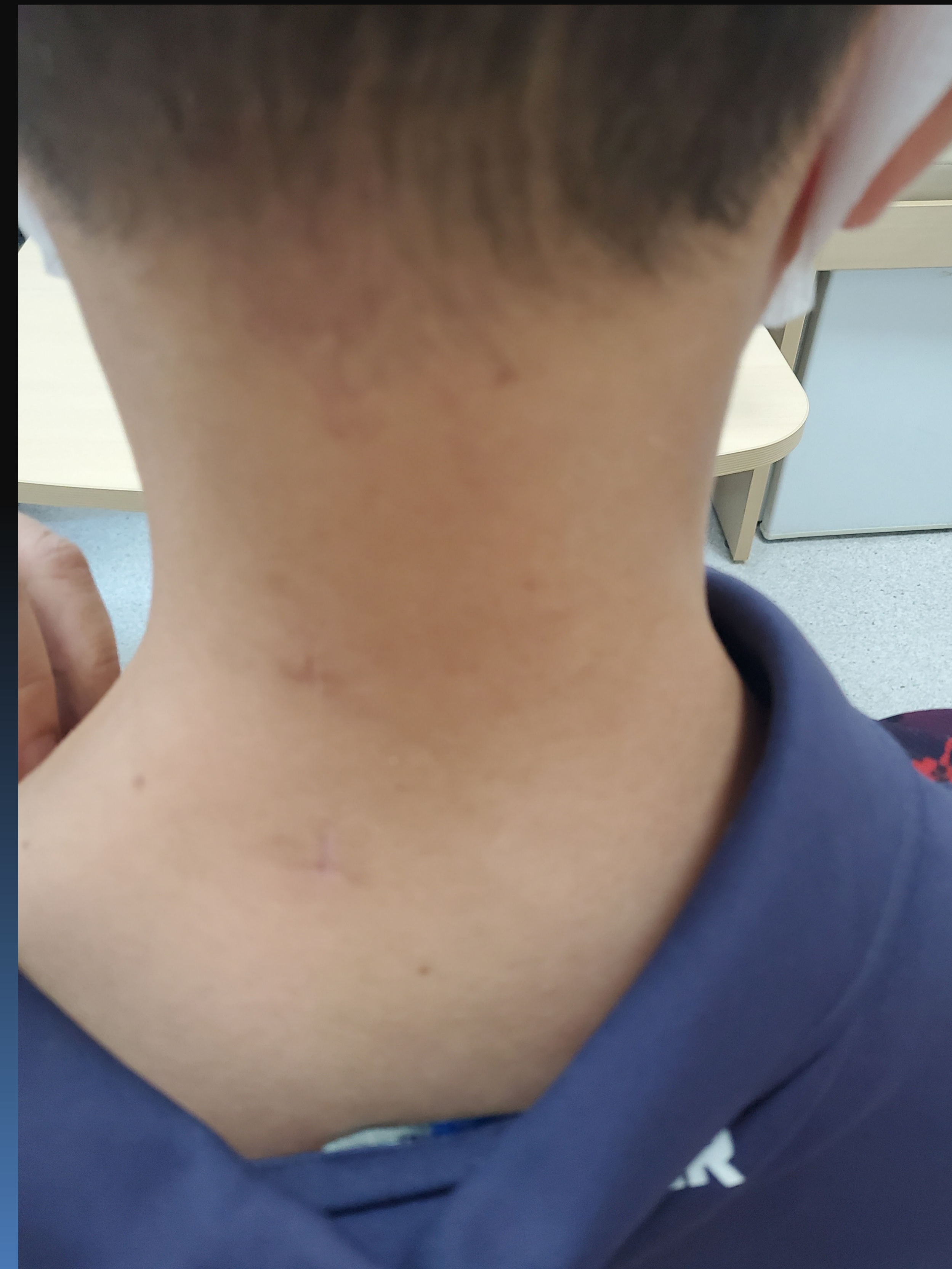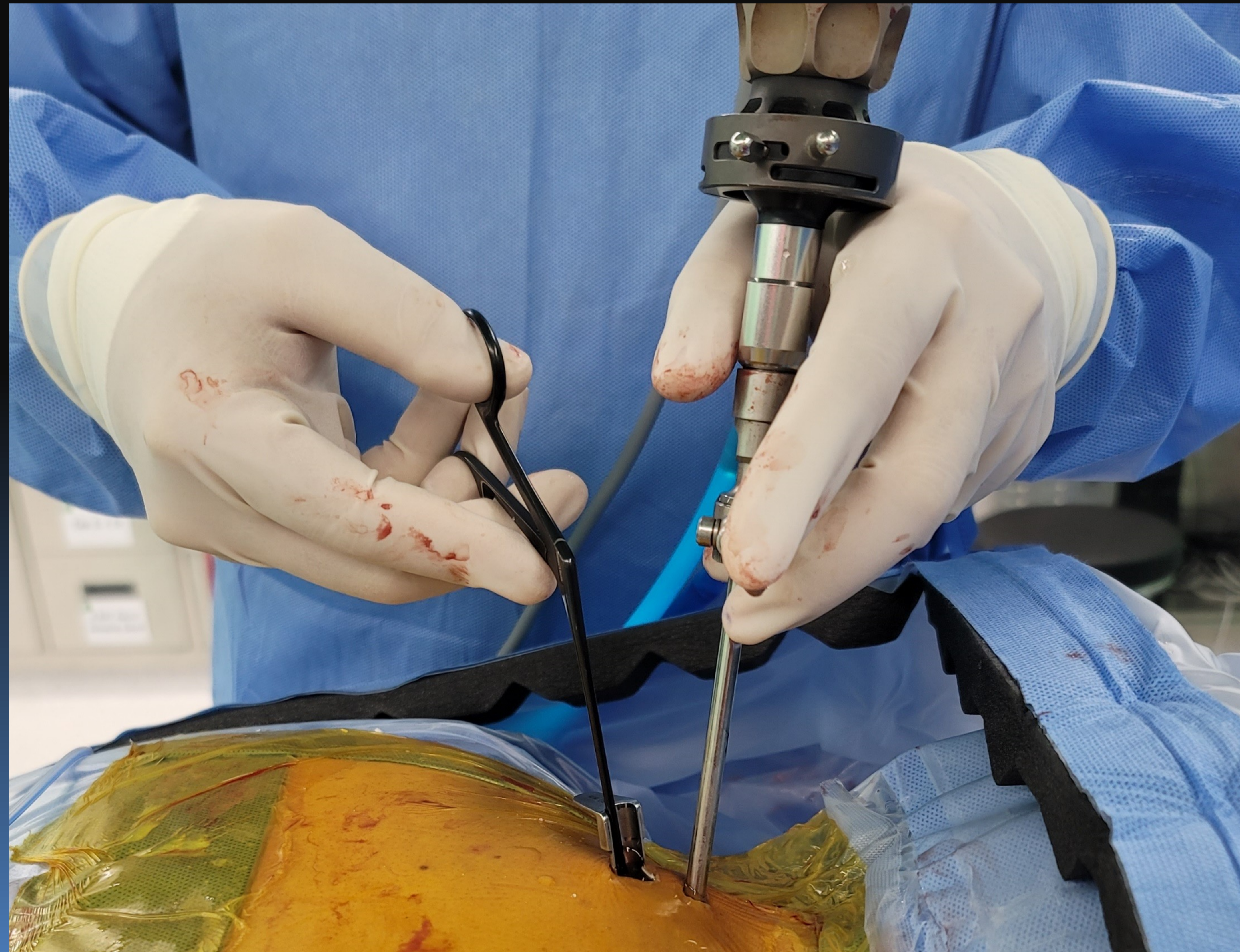








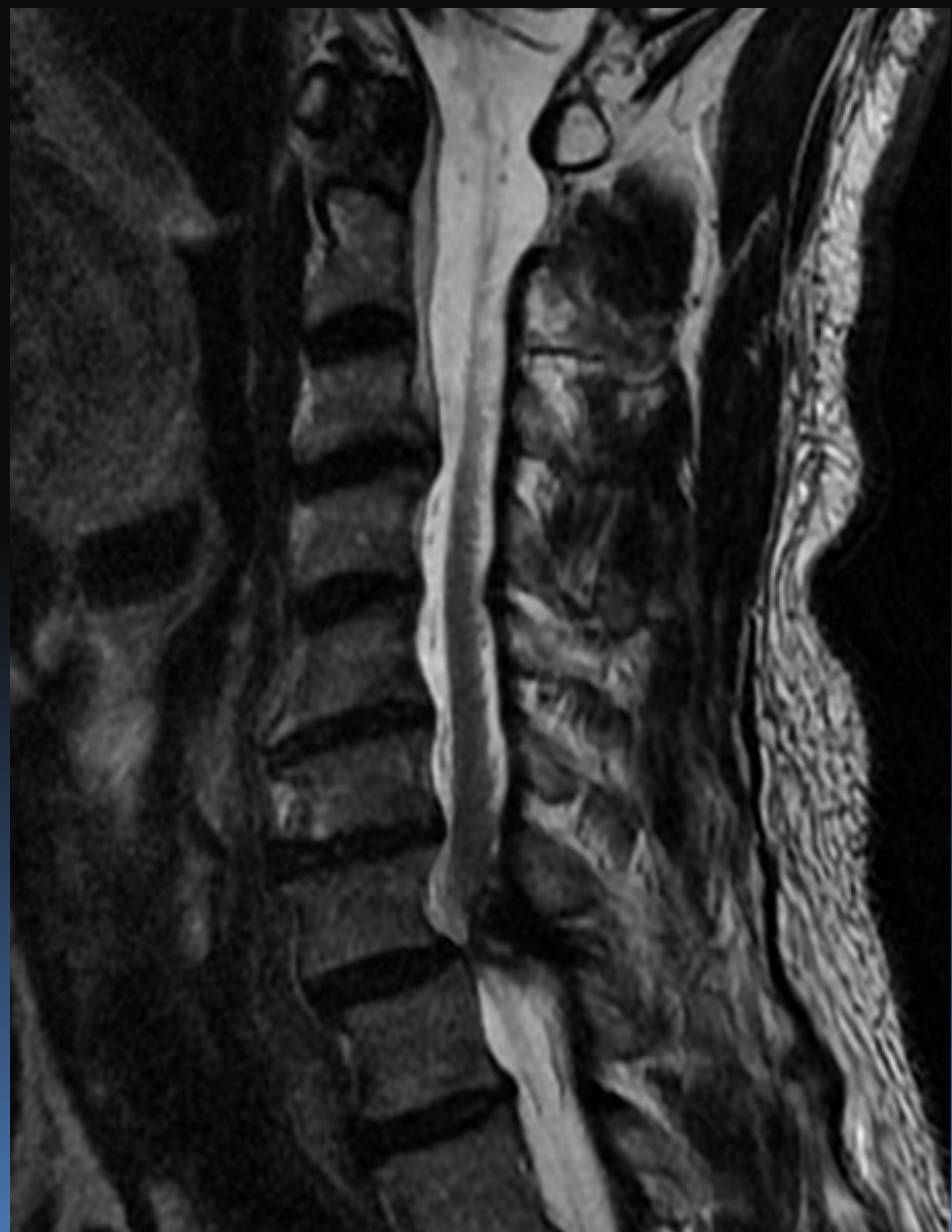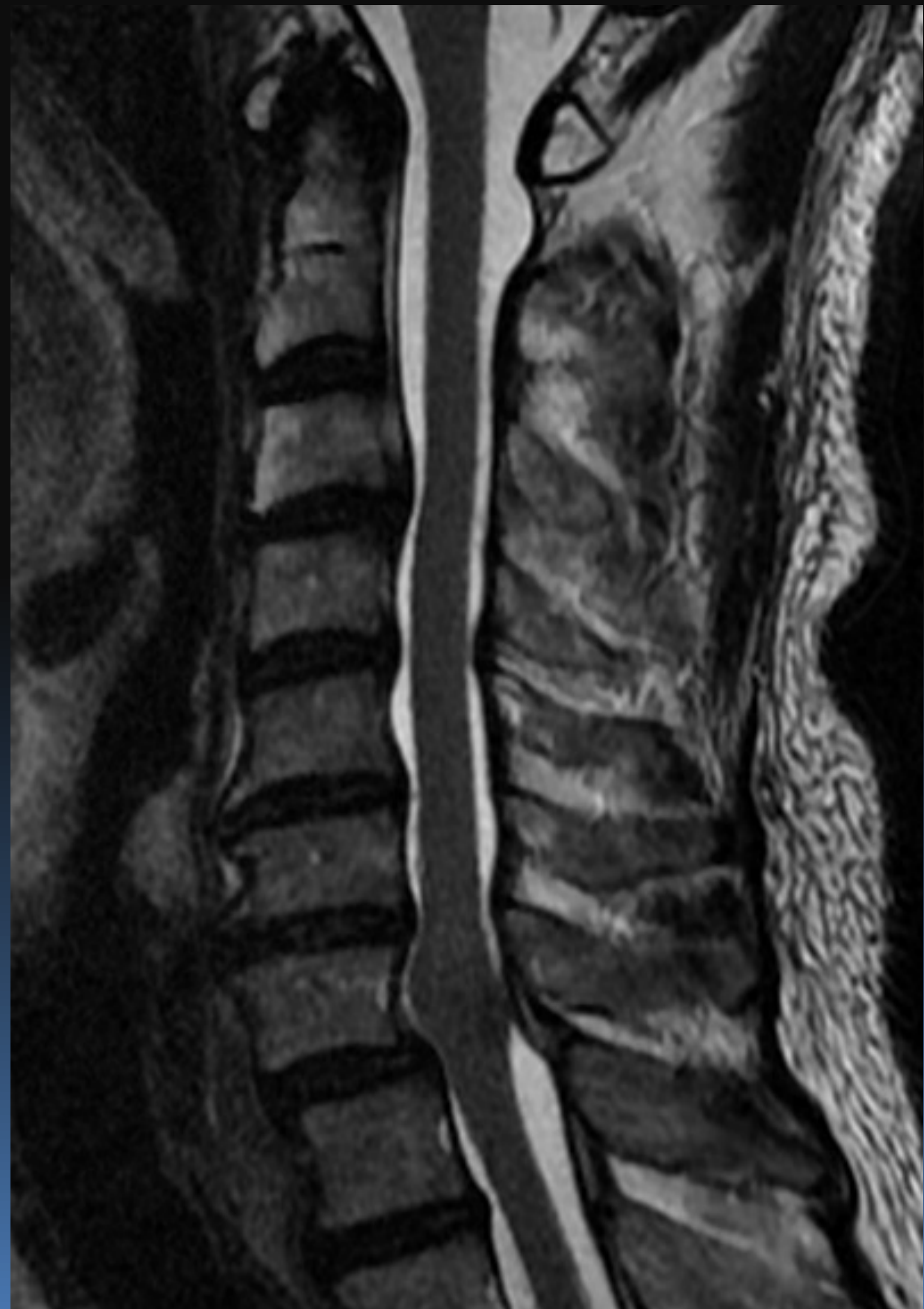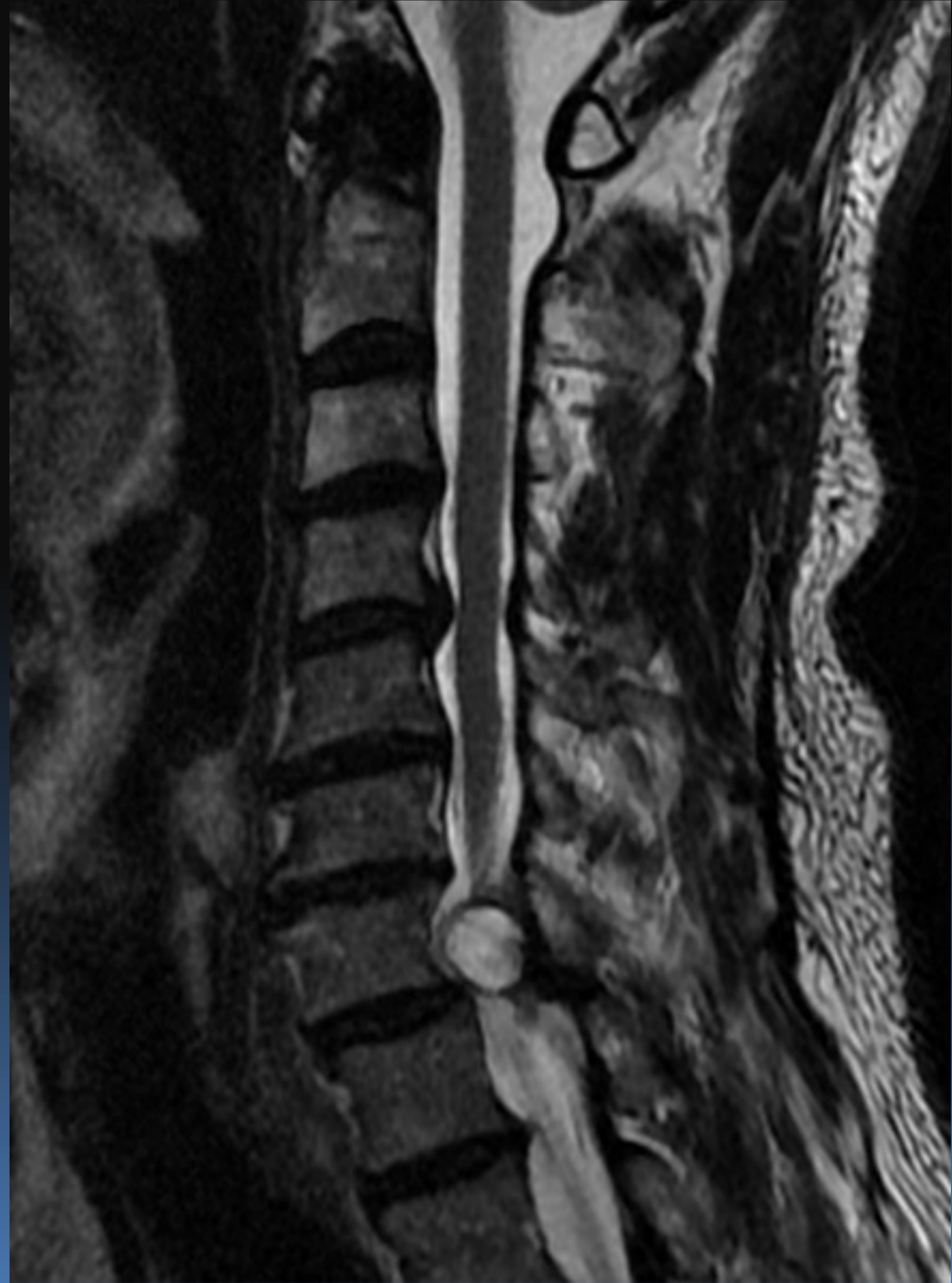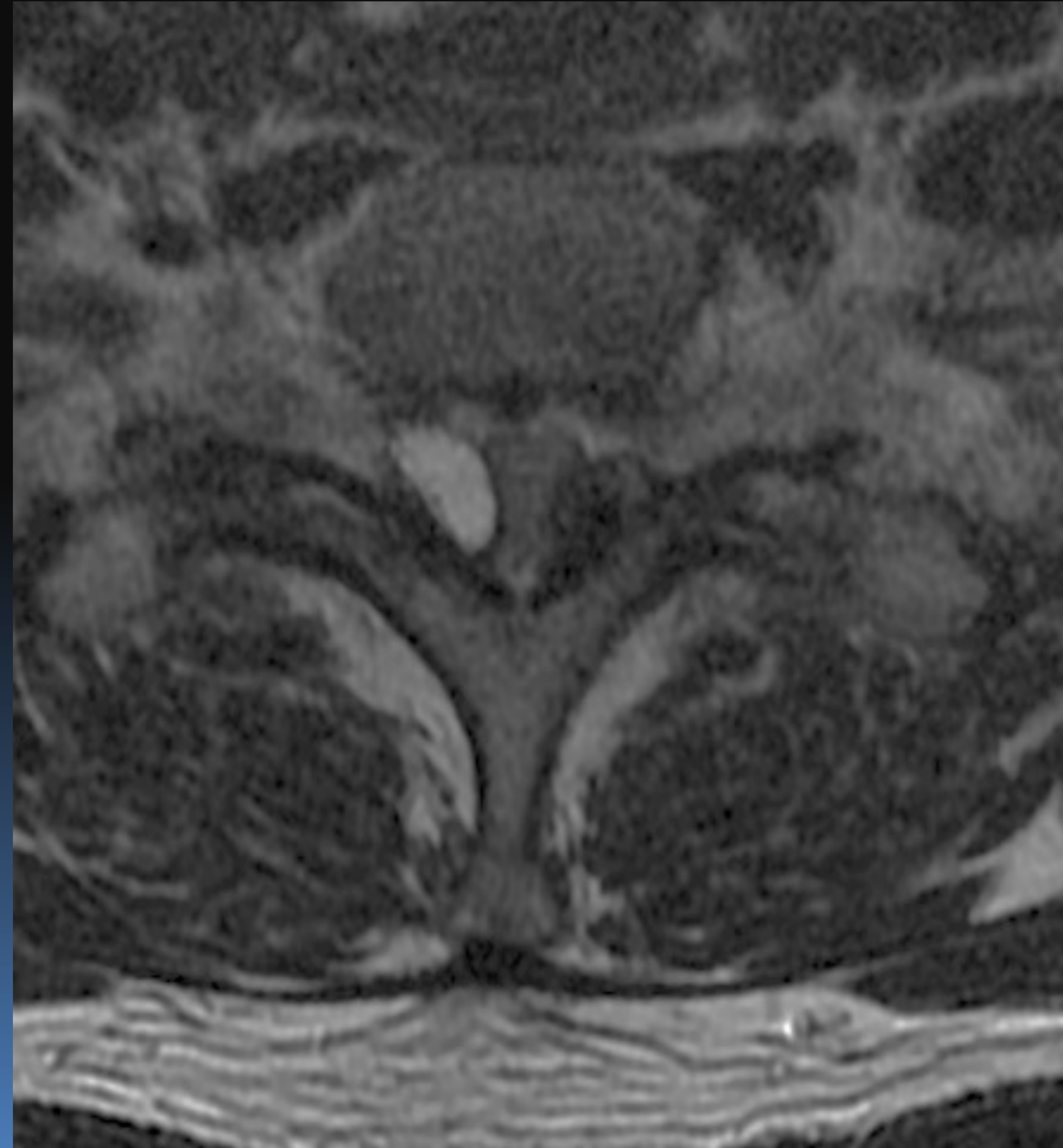
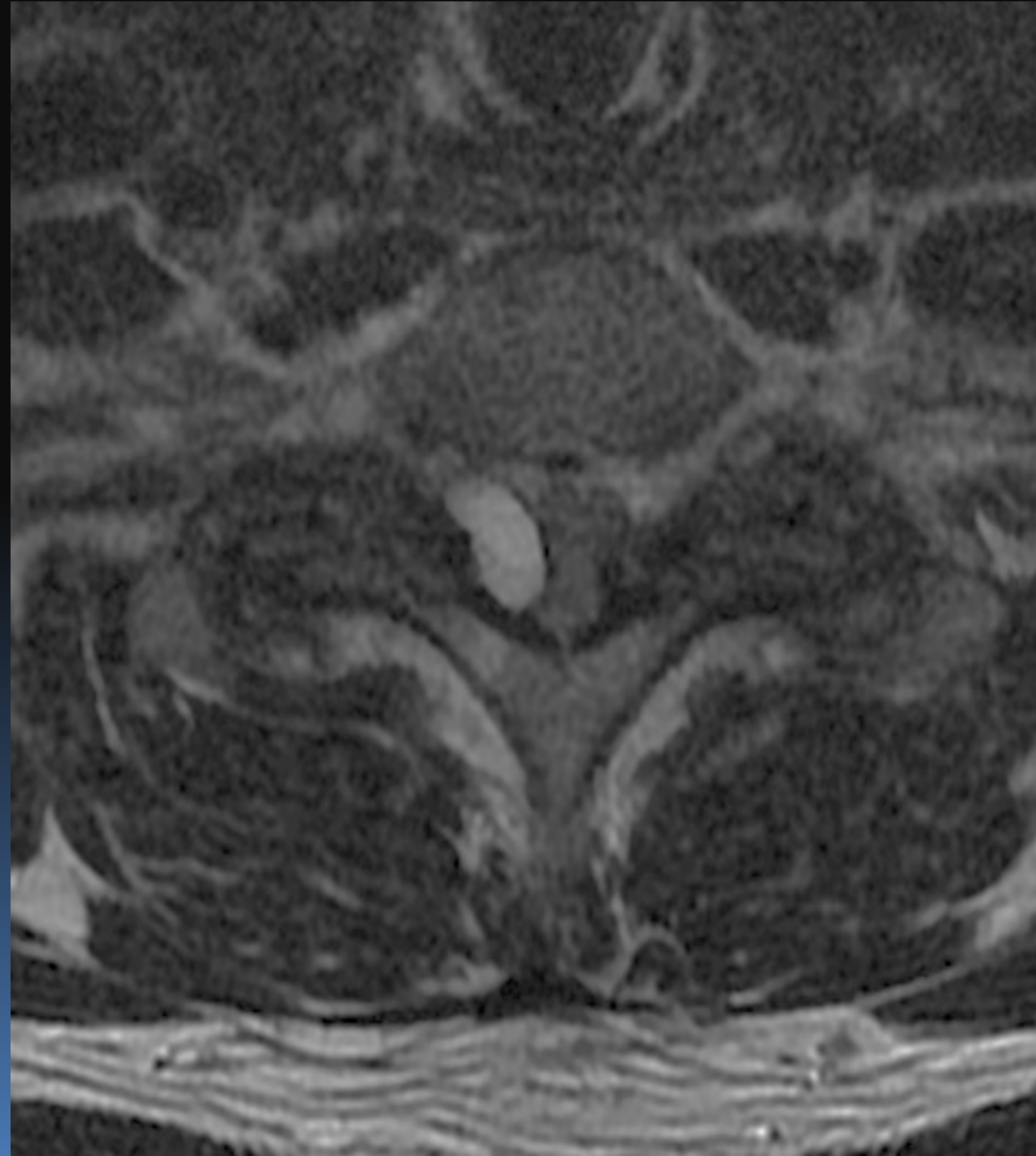
# Skin wound

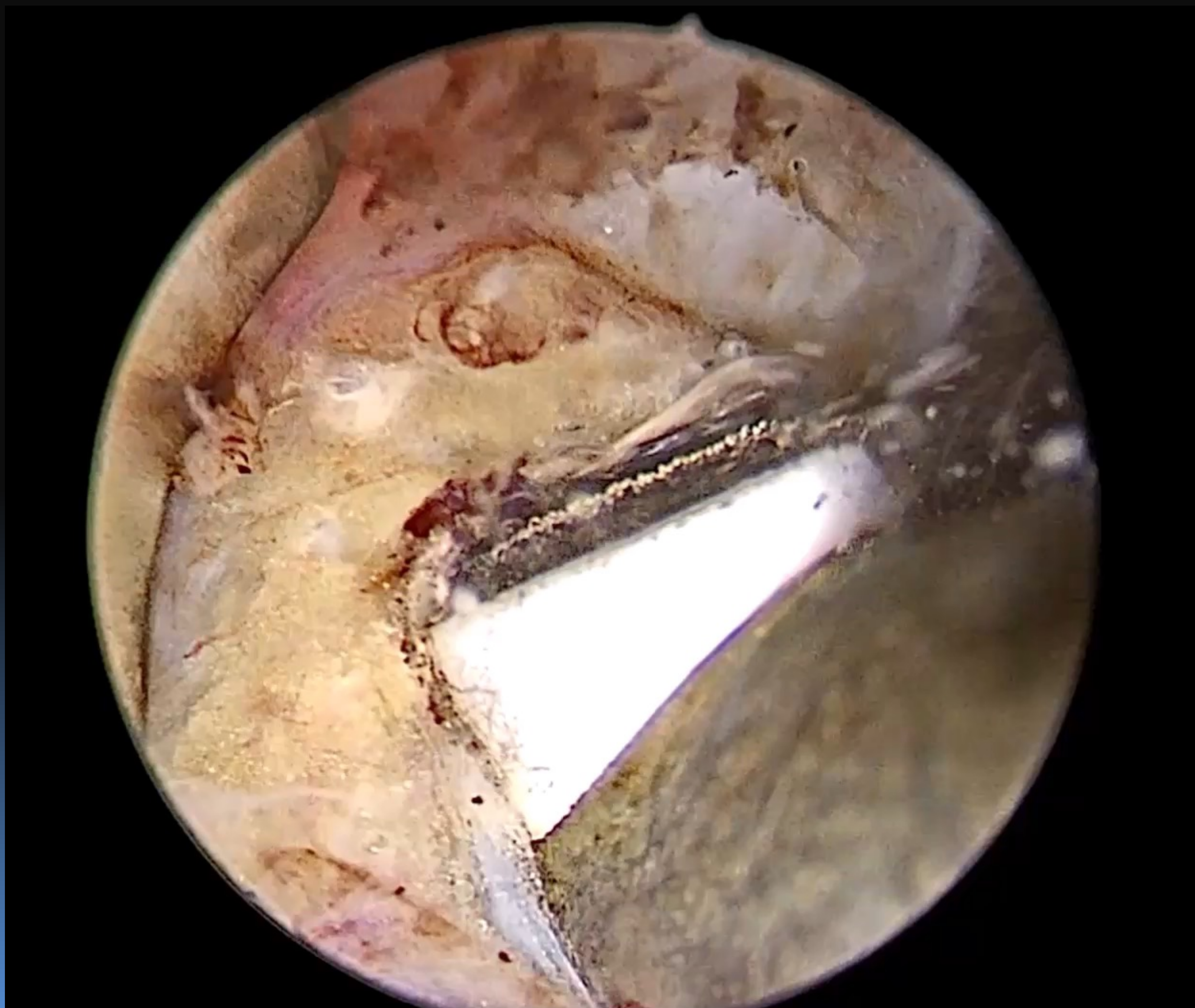
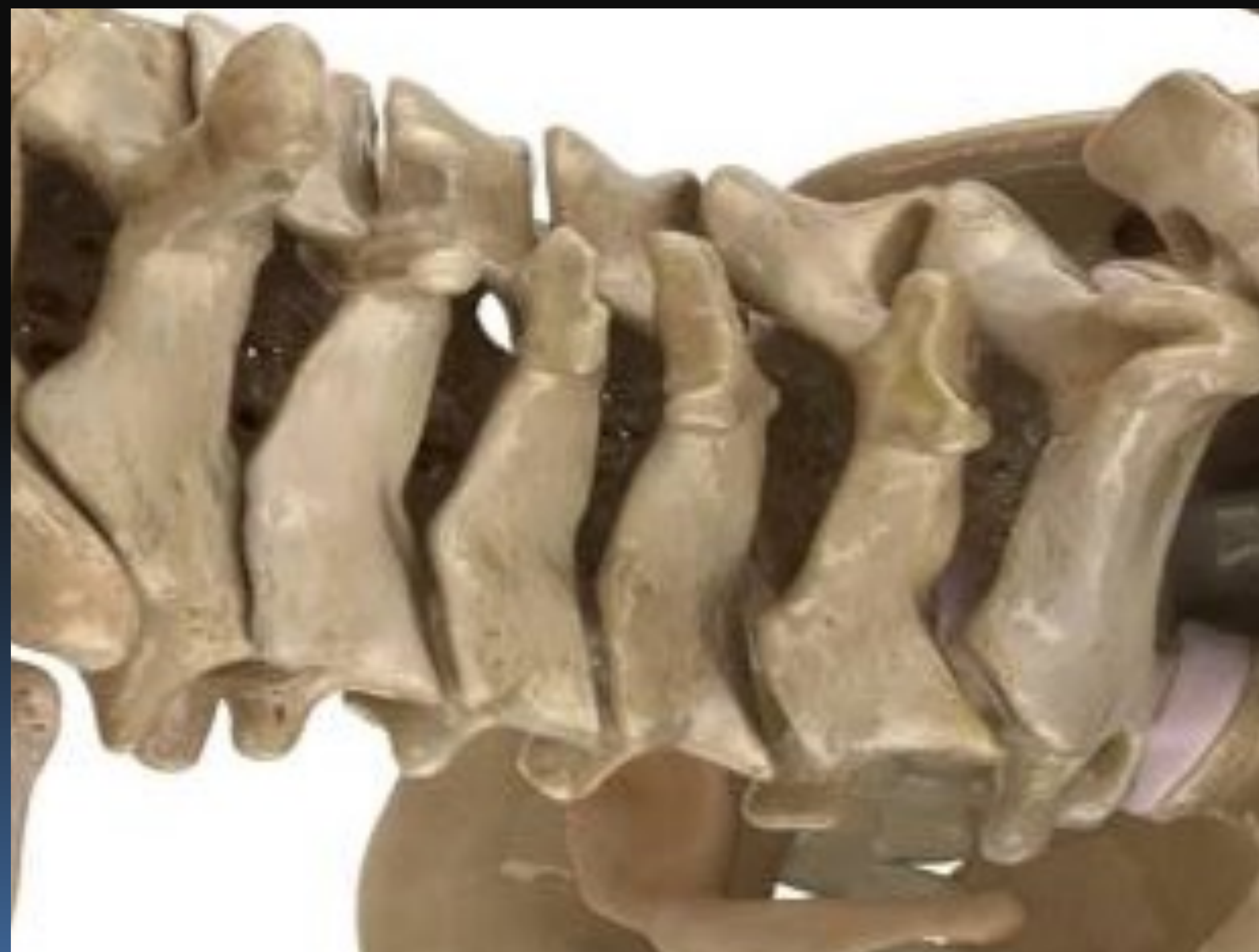
**61/M**

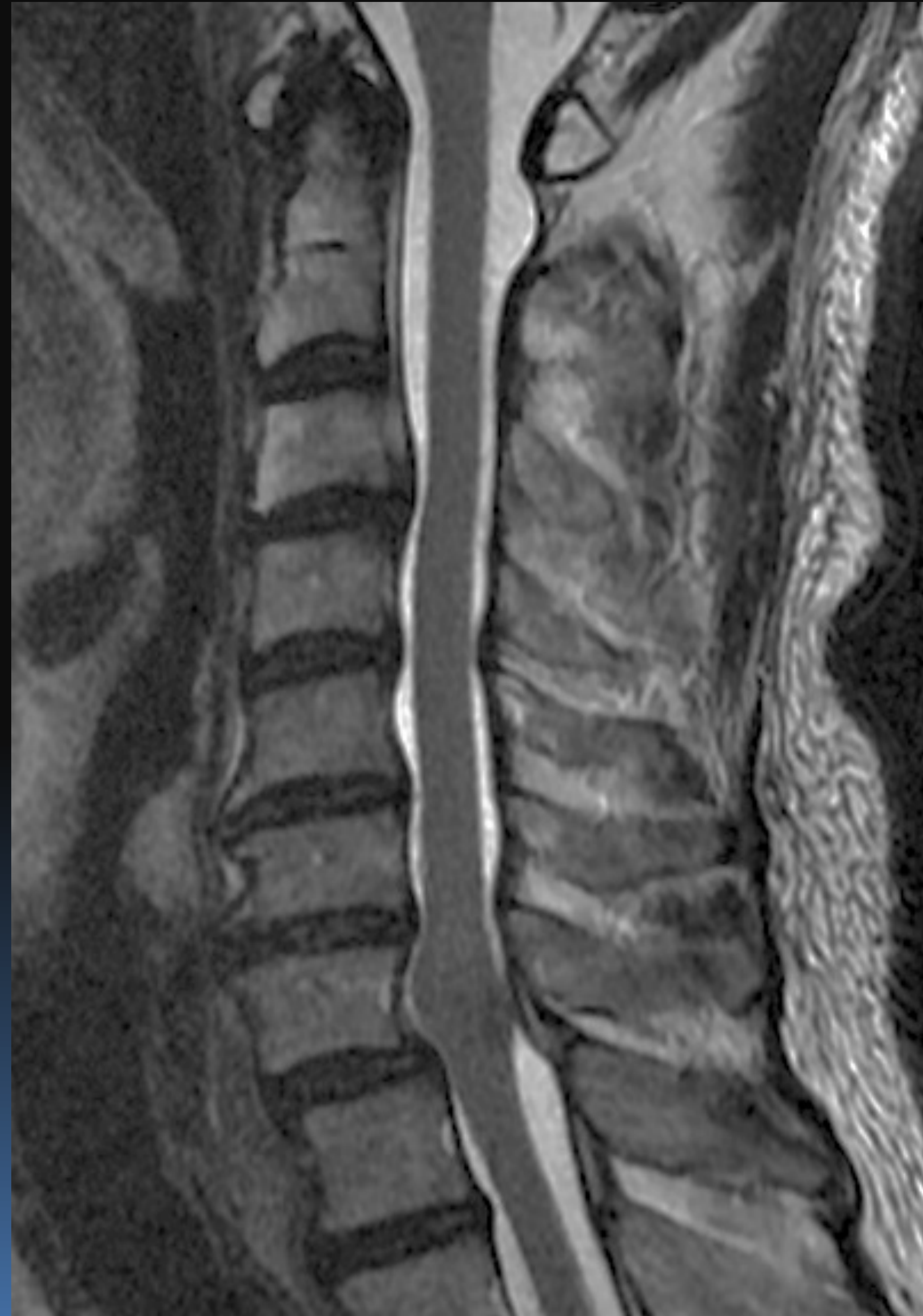- **Bilateral hands grasp power weakness**
- **Bilateral hands tingling**
  
- **Hoffman sign +**



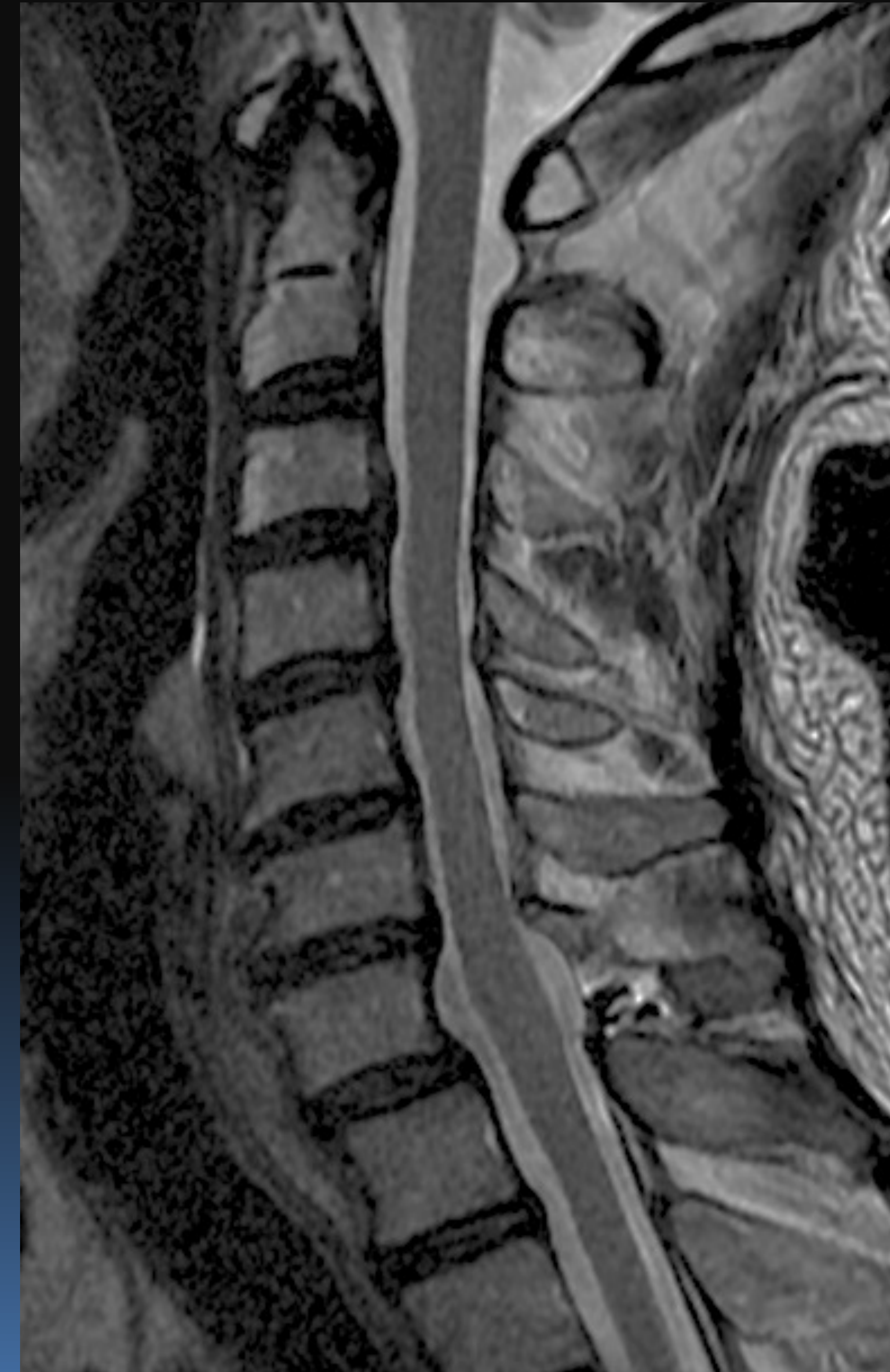



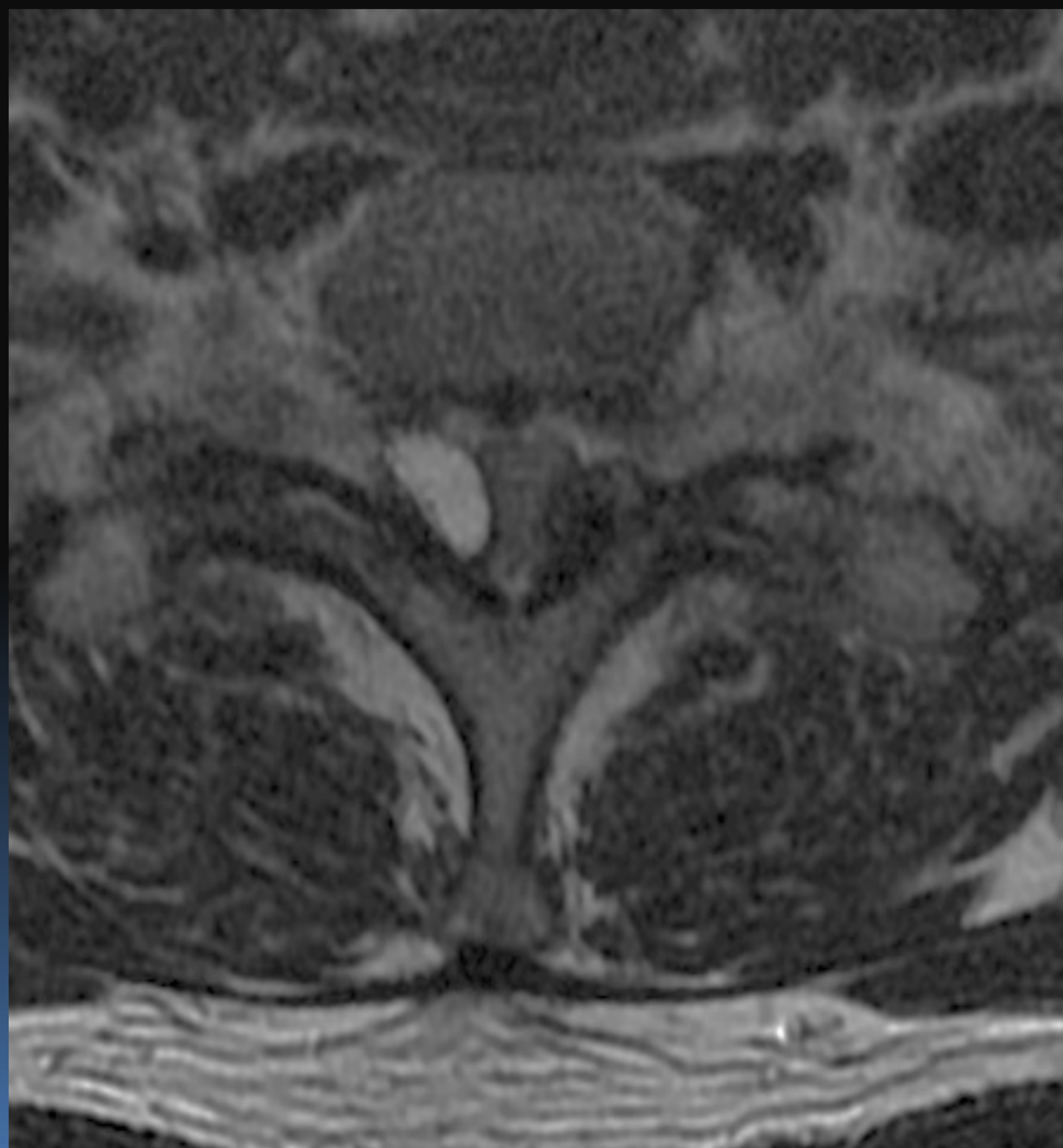




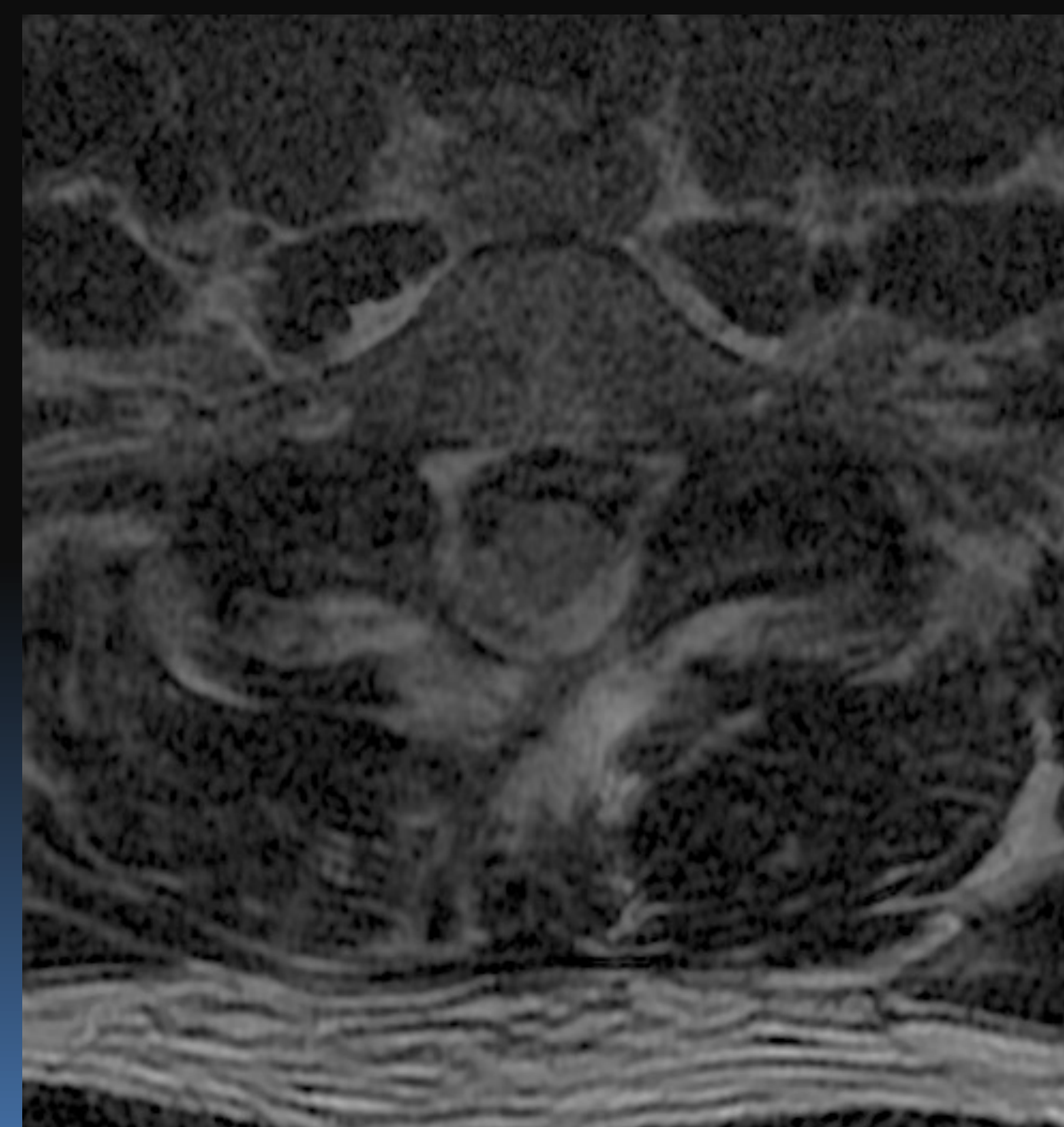
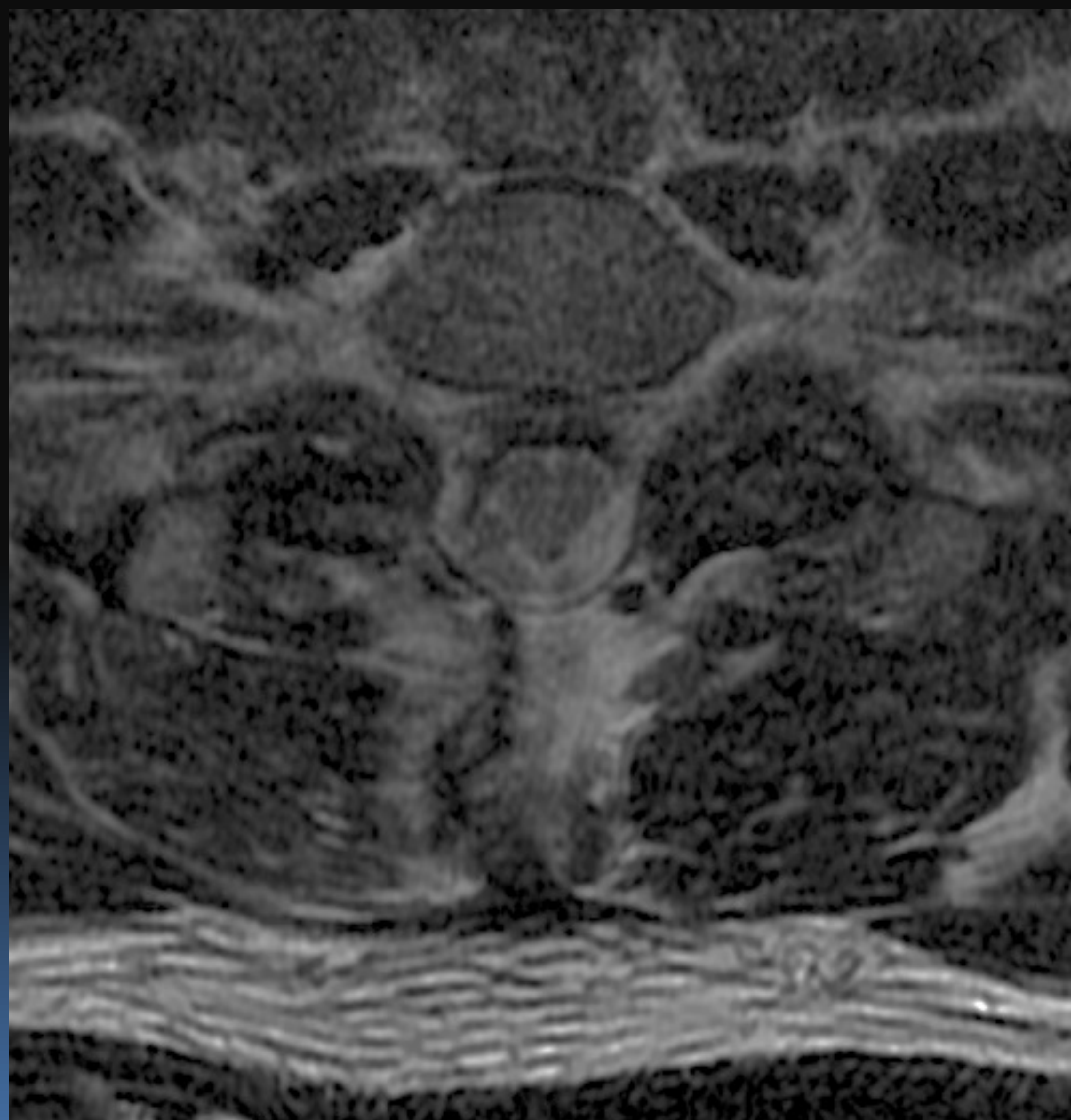
**Preoperative MRI**



**Post-operative MRI**



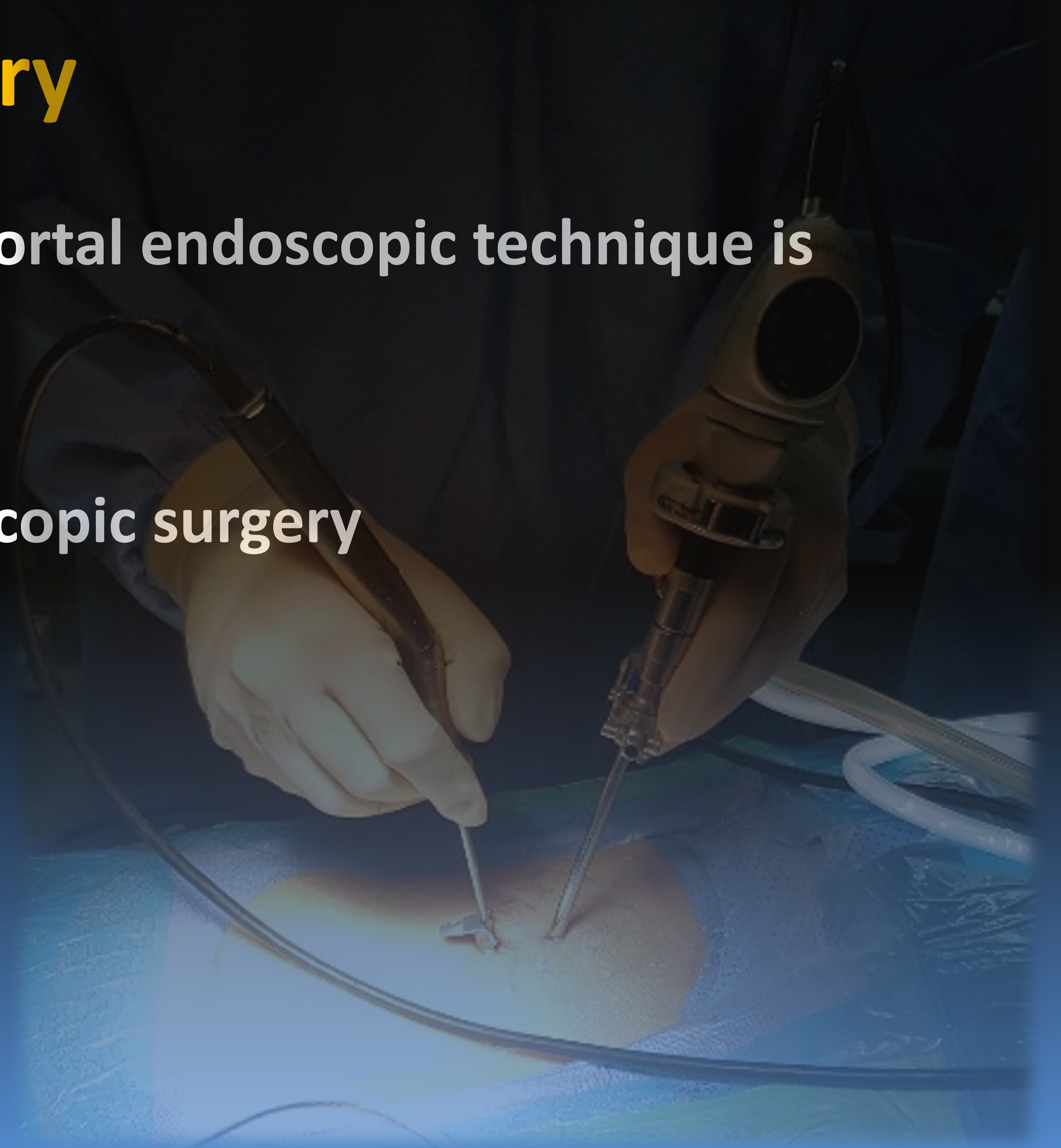
**Preoperative MRI**

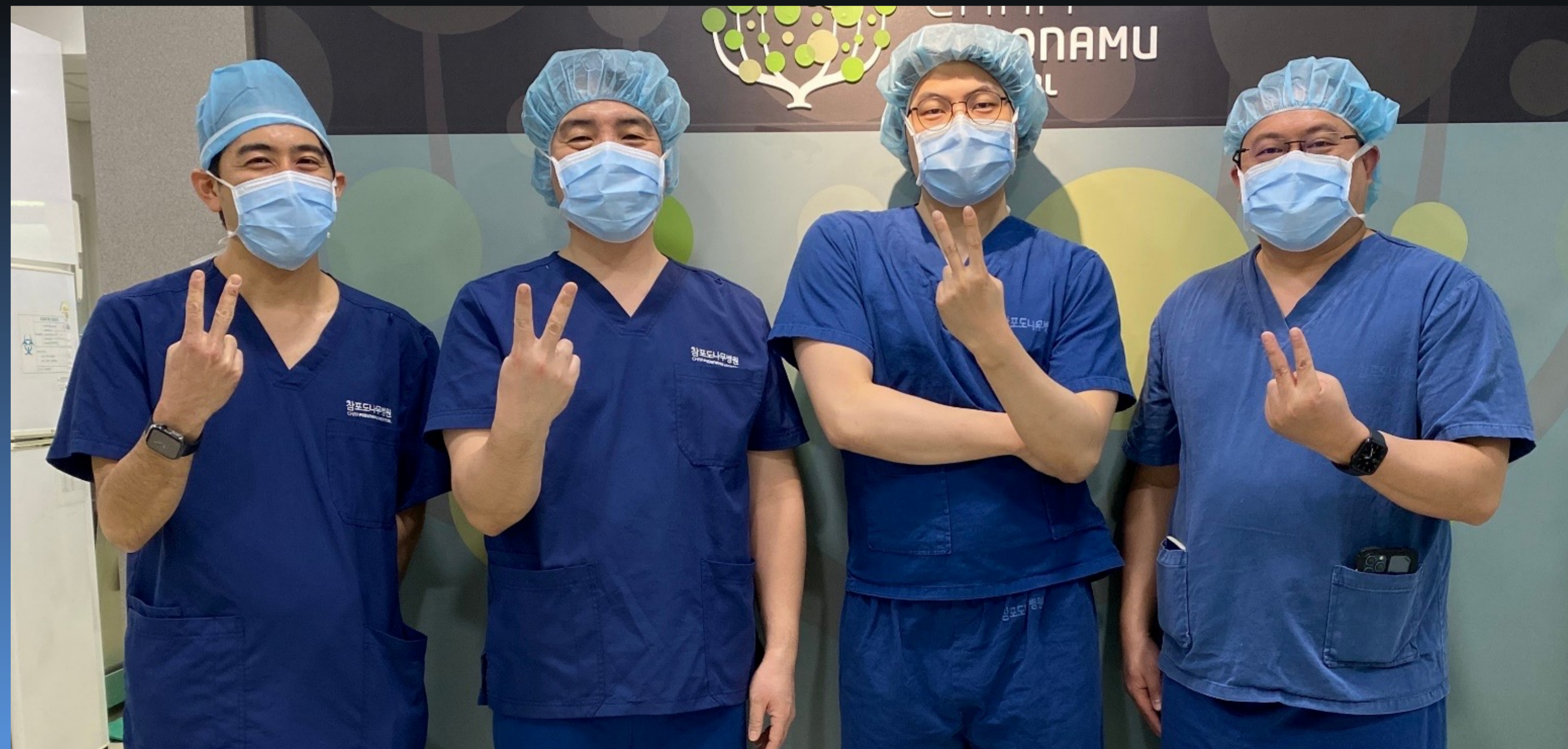
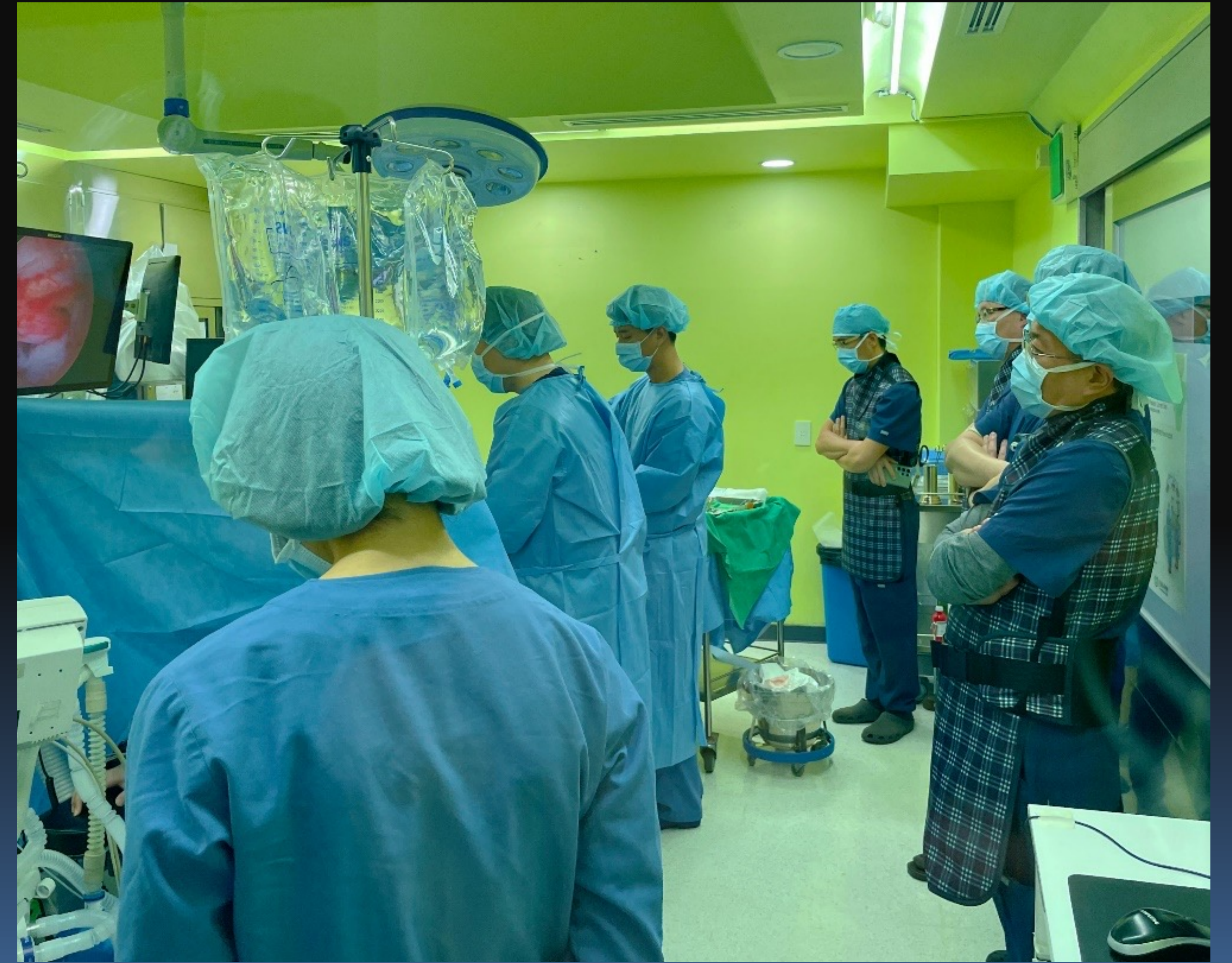
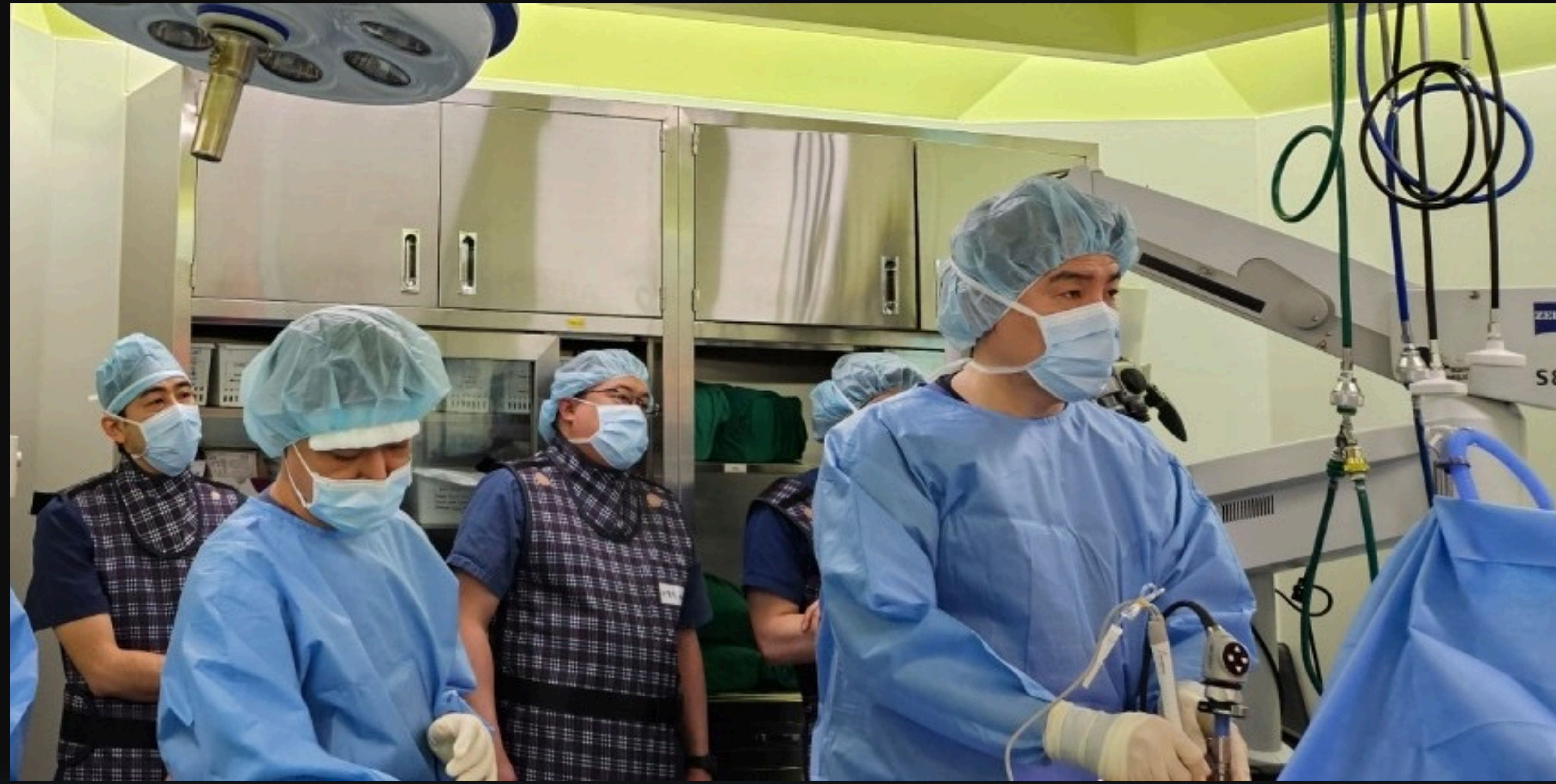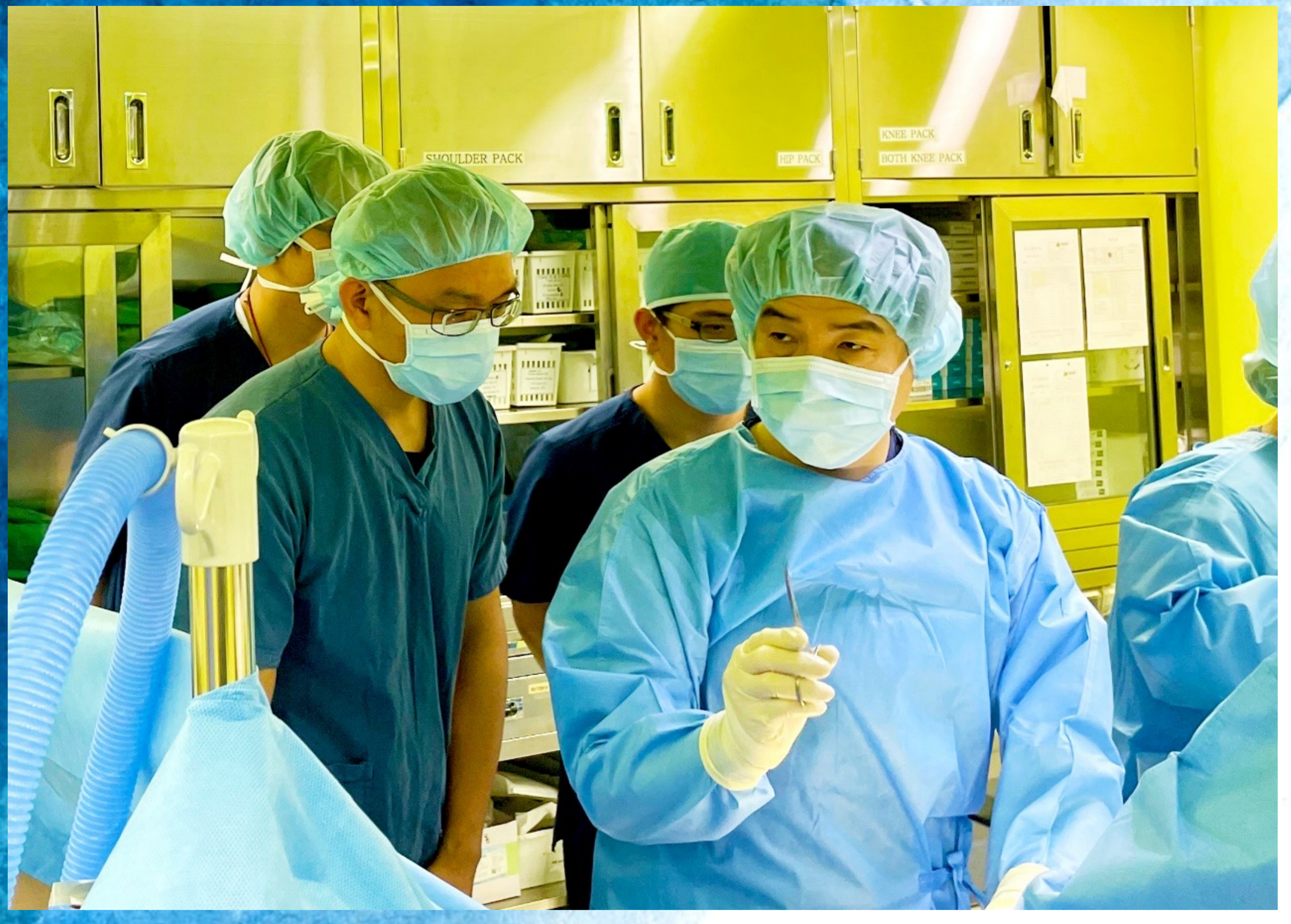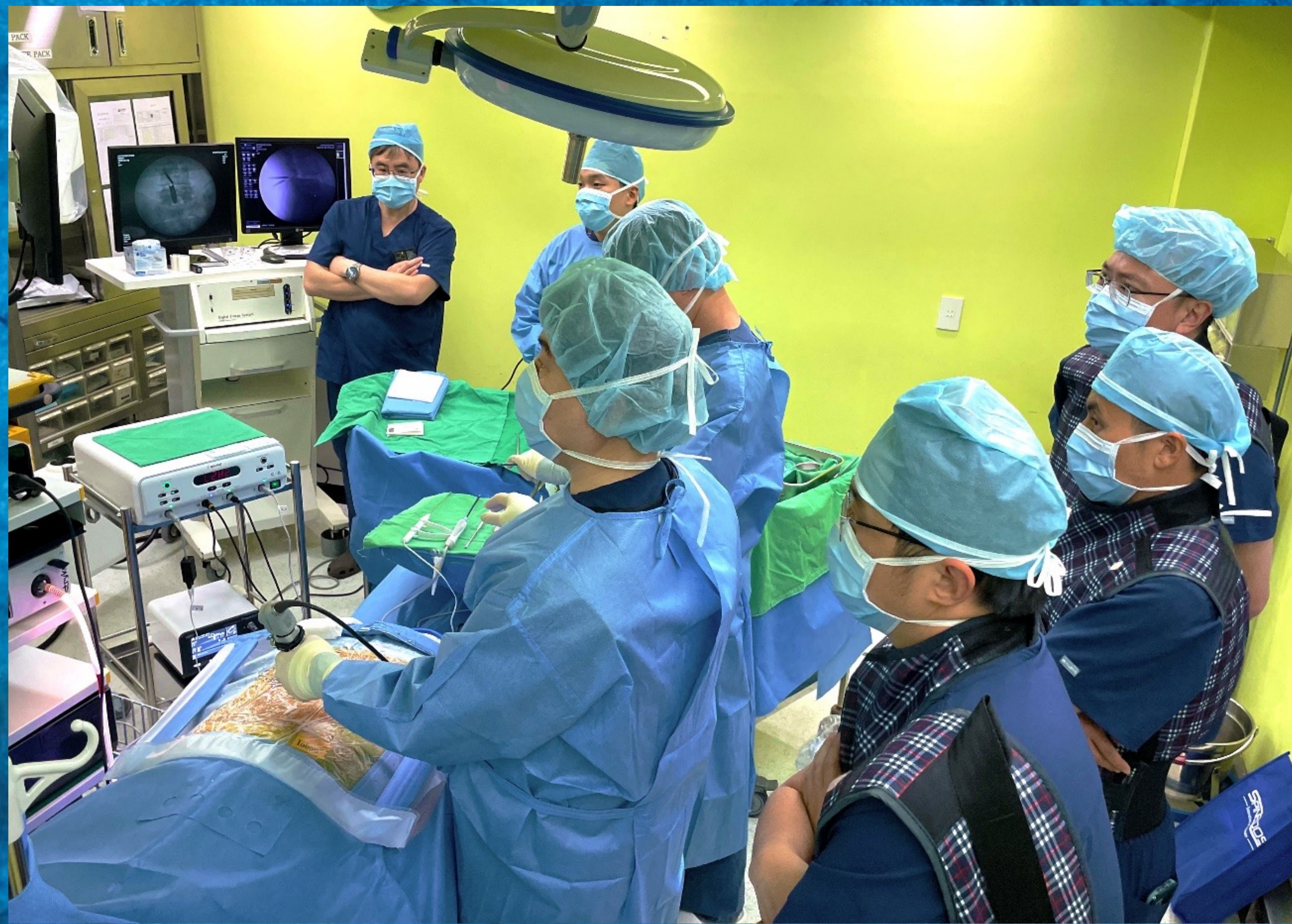**Post-operative MRI**

# Summary

- The surgical endoscopic view of the biportal endoscopic technique is similar to that of Microsurgery
- Experiences of microsurgery and endoscopic surgery
- Irrigation fluid pressure and drainage
- Favorable outcome







**From Taiwan**

**10 times visit**

**70 Taiwan spine doctors**

